



Prevalence of foot lesions in cattle in Mosul, Iraq

Hafidh, I. Al-Sadi¹, M.N. Mohamed², M.B. Najm Aldeen² and A.A. Easaa²

¹Department of Veterinary Pathology and Poultry Diseases, College of Veterinary Medicine, University of Mosul, Mosul, Iraq; ²Veterinarians, Veterinary Hospital, Bab-Sinjar, Mosul, Iraq

Abstract

This study was conducted to record for the first time in Mosul area, Iraq, the prevalence of bovine foot lesions during from 16 December 2010 to 20 February 2011. The feet of randomly selected 226 cows were examined and the types of lesions were recorded. Foot lesions were found in 50 from 226 (22.12%) cows. These lesions arranged in order of decreasing frequency were foot rot (5.75%), ulcers of the hooves (3.53%), overgrown hooves (3.09%), coronary band abscesses (2.65%) and hoof abscesses (2.65%). Other types of lesions were of equal frequency (0.88%) and included papillomatosis (skin warts), hemorrhage in various parts of the hoof, bovine interdigital dermatitis, FMD lesions, and congenital defects. The gross and microscopic features of these lesions were similar to those reported in literature. From results of this study, it was concluded that bovine foot lesions are common in Mosul area and that further studies are needed to elucidate the causes, therapy and control of these conditions.

Keywords: Lesions, Feet, Cattle

Introduction

Worldwide, lameness is a major problem in cattle, particularly in dairy herds. The incidence of lameness differs in various countries and even within the same country. In UK, the incidence of lameness was 8.9% per annum (Hedges et al., 2000). In New Zealand, incidences of lameness were 38, 22 and 2% in three different herds (Tranter and Morris, 1991). In USA, 11.8% of lactating dairy cows were clinically lame in summer and 14.8% in the winter season (Wells et al., 1995). In another study in UK, incidence rate of 54.6% have been reported (Clarkson et al., 1996).

Several studies attempted to record the frequency of various lesions causing lameness (Russell et al., 1982; Tranter and Morris, 1991; McLennan, 1988; Clarkson et al., 1996 and Hedges et al., 2000). Results of these studies need to be interpreted with care since some of them involved farmer-recorded cases while others involved veterinary reported-recorded cases (Blowey, 2004). According to the study of Hedges et al. (2000), the types of lesions recorded as causing lameness (cases /100 cows per year) are sole ulcer (13.90), white line disease (12.70), interdigital necrobacillosis (7.20), foreign body penetration (3.10), interdigital dermatitis

(12.00), interdigital skin hyperplasia (1.20), overgrown sole/ bruising (2.00), vertical fissure (sandcrack) (0.54), deep sepsis (0.45), heel ulcers (5.80) and axial wall fissures (1.07). A major British survey in 1977 revealed that in 7526 cases of lameness most lesions (88.3%) occurred in the feet and 84% of foot lesions were in the hind feet. The remaining 11.7% of cases occurred in the legs and trunk (Russell et al., 1982).

In Iraq in general and in Mosul area in particular, information concerning the prevalence of lameness in cattle and the type of lesions causing lameness is still lacking. Therefore, this study was undertaken to record the prevalence of foot lesions in cattle in Mosul area, Iraq.

Materials and Methods

The feet of 226 cattle were examined from 16th December 2010 to 17th February 2011. The animals were selected randomly from bovine cases that were presented to the Veterinary Medical Teaching Hospital, College of Veterinary Medicine, University of Mosul, Mosul, Iraq as well as cattle that were slaughtered during the same period in the main slaughterhouse in Nenevha province. Examination of the various parts of

Corresponding author: Hafidh Al-Sadi, Department of Veterinary Pathology and Poultry Diseases, College of Veterinary Medicine, University of Mosul, Mosul, Iraq

the foot was done grossly and the lesions were photographed using digital camera. Tissue specimens were collected from the gross lesions and were fixed in 10% formalin for 48 hours. Following fixation the specimens were trimmed to suitable size, washed under tap water, dehydrated in ascending grades of alcohol, cleared in xylol and embedded in paraffin wax (60-62 °C melting point). Sections of 4-6 µm thickness were cut and stained with hematoxylin and eosin (Kiernan, 2000). The stained sections were examined under a light microscope and photographs were taken using a digital camera.

Results

Lesions of the foot were found in 50 out of 226 cows (22.12%). The types of these lesions and their prevalence are presented in Table 1 and they included foot rot (5.75%), ulcers (3.53%), overgrown hoof (3.09%), coronary band abscesses (2.65%), hoof abscesses (2.65%), foot warts (0.88%), digital dermatitis (0.88%), foot and mouth disease (FMD) (0.88%), and congenital anomaly of the foot (0.88%). The gross and microscopic features of these lesions were similar to those reported in the literature and some of them are shown in Figures 1 to 10.

Table 1: Prevalence of the different lesions of the foot in 50 out of 226 cows

Lesions	Cases	
	Number	%
Foot rot	13	26
Ulcers	8	16
Overgrowth of the claws	7	14
Coronary band abscesses	6	12
Hoof abscesses	6	12
Dermal papillomatosis	2	4
Hemorrhages	2	4
Bovine interdigital dermatitis	2	4
Foot-and-mouth disease	2	4
Congenital defect of the foot	2	4
Total	50	100

Discussion

In this study, the prevalence of foot lesions in cattle in Nenevha province was 22.12%. This value is lower than that reported in cattle in other parts of the world. Tadich et al. (2010) examined the feet of 676 cows from 34 large herds and 422 cows from 57 small herds in southern Chile. They found that the prevalence of lesion by type ranged from 65% of cattle with at least one white line lesion to 2% of cattle with and interdigital growth. Relatively recent estimates from Europe indicate that prevalence of foot lesion is approximately 50% in tie-stall housing systems

(Sogstad et al., 2005) and 70 to 80% in free-stall housing (Somers et al., 2003; Sogstad et al., 2005). In these and other studies, there is considerable herd variation in lesion. Furthermore, herd level variance

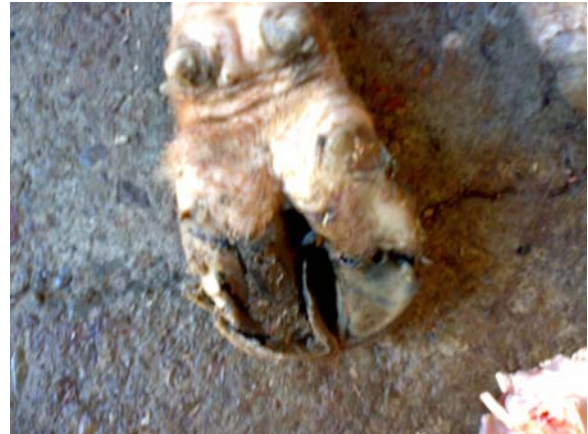

Fig. 1: The foot of a cow affected with foot rot. Note swelling of the foot, separation of the digits, and wear of the claw.

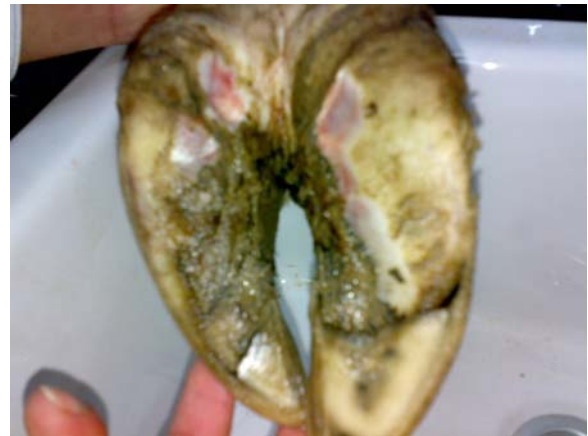

Fig. 2: Ulcers of the heel of a cow.



Fig. 3: The limbs of a cow with overgrown hooves



Fig. 4: Hemorrhages in all parts of the foot of a cow

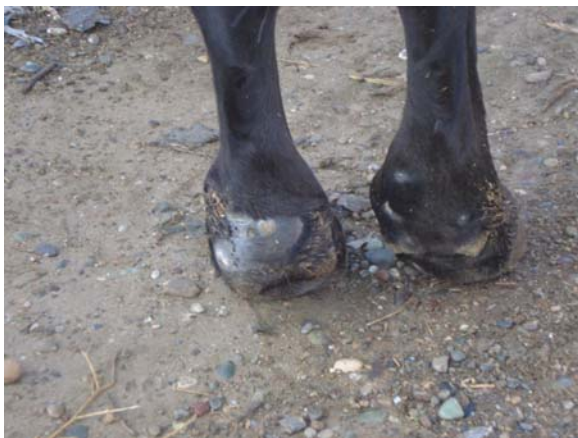

Fig 5: Hind limbs of a cow with FMD. Note the presence of ulcers and scars of variable sizes



Fig. 6: A congenital defect in the foot of a cow

makes a large contribution to the total variance for most lesions (Sogstad et al., 2005; Holzhauser et al., 2006). Such variations suggest that herd level risk factors may be important determinants of lesions and lameness in dairy cattle (Cramer et al., 2009).

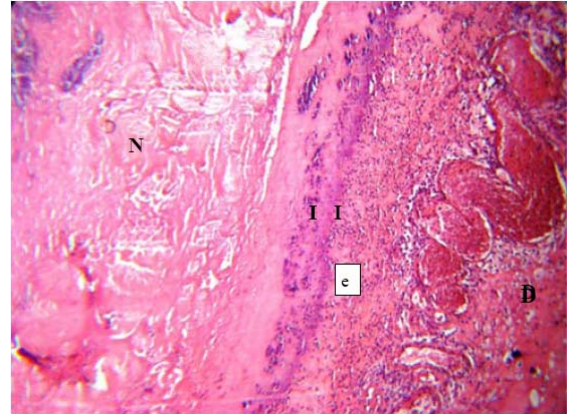


Fig. 7: Cross section of the soft tissue of the coronary band region in the foot of a cow affected with coronary band abscesses. A necrotic area (N) separated by an inflammatory zone (I) from dermis (D). H & E X90

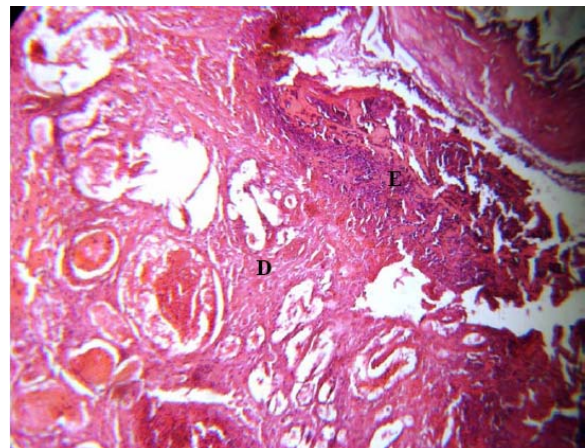


Fig. 8: Another section from the previous case (Fig.8). Note necrosis of the epidermis (E) and the dermis (D). H & E X90

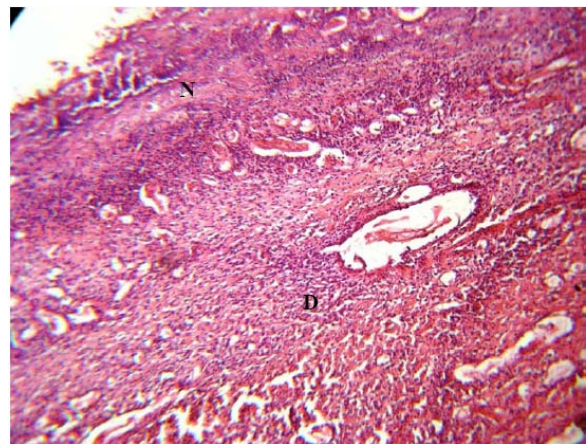


Fig. 10: Cross section of the soft tissue of the coronary band region in the foot of a cow affected with coronary band abscesses. Note necrosis (N) and the infiltration of inflammatory cells (predominantly neutrophils) in the dermis (D). H & E X90.

In this study, foot rot was reported in 13 cows out of 226 (3.8%) and it constituted 26% of the foot lesions. Bacterial causes of this lesion included *Fusobacterium necrophorum* and *Bacteroides melaninogenicus* (Divers and Peek, 2008). Early lesions appear as mild cellulitis and swelling, and a fine diphtheritic membrane on the skin between the hooves (Edmondson, 2002). Liquefactive necrosis then appears and produces longitudinal fissuring and scabby exudate. Extensive necrosis of the interdigital area, organization of the exudate, and fibrosis could be seen (Edmondson, 2002).

Ulcers of the foot were encountered in 8 out of 226 (3.53%) and constituted 16% of the foot lesions. The ulcers were seen in both the lateral claws of the rear feet and the medial claws of the forelimbs. Moisture, manure, excessive wear and poor hoof trimming are considered predisposing factors to the occurrence of ulcers (Montoya, 2006; Shearer and Van Amstel, 2009).

Overgrown hooves were found in 7 out of 226 (3.09%) cows and constituted 14% of the foot lesions. This condition causes discomfort and prone the hoof to cracking which permits the entrance of bacteria with the resultant infection (Mason and Offer, 2007).

In this study, abscesses of the coronary band were detected in 6 out of 226 (2.65%) cows and represented 12% of the foot lesions. The most common site at this type of lesion is the posterior quarter of the medial claw. This finding is in agreement with that recorded by Divers and Peek (2008).

Sole abscesses were recorded in 6 out of 226 (2.65%) cows and constituted 12% of the foot lesions. These abscesses were observed limited by the hoof wall. This finding is similar to that reported by Cate (2010).

Other lesions that were found in this study included hemorrhage, papillomatous digital dermatitis, FMD lesions, and congenital defect of the foot, with prevalence of 0.88% for each of them. A great variation exists in the prevalence of these lesions in various parts of the world (Read et al., 2010).

Conclusion

It was concluded that foot lesions are common in cattle in Mosul area, Iraq and that further studies are needed to elucidate the causes, pathogenesis, treatment and control of these lesions.

References

Blowey, R.W. 2004. Lameness in the foot, in: Andrews. AH., Blowey. RW., Boyd. H. and Eddy. RG (editors), *Bovine Medicine: Diseases and Husbandry of Cattle*. Blackwell Science, Oxford. Pp: 409-434.

- Cate, B. 2010. Problems in the feet of cattle. updated: November 15, 2010. Retrieved from internet: <http://i-ehow.com/images/a07/4v/co/problems-feet-cattle-1.1-800x800.jpg>.
- Clarkson, M.J., Downham, D.Y., Faull, W.B., Hughes, J., Manson, F.J., Merritt, J.B., Murray, R.D., Sutherst, J.E. and Ward, W.R. 1996. Incidence and prevalence of lameness in dairy cattle. *Veterinary Record*, 138: 563-567.
- Cramer, G., Lissemore, K.D., Guard, C.L., Leslie, K.E. and Kelton, D.F. 2009. Herd-level risk factors for seven different foot lesions in Ontario Holstein cattle housed in tie stalls or free stalls. *Journal of Dairy Science*, 92: 1404-1411.
- Divers, T.J. and Peek S.F. 2008. *Rebhun's Diseases of Dairy Cattle*. 2nd (ed.) Saunders / Elsevier, Philadelphia, Pp: 467-503.
- Edmondson, A.J. 2002. Interdigital Necrobacillosis (Foot rot) of Cattle, in: Smith. BP (editor), *Large Animal Internal Medicine*. Mosby, St. Louis, Pp: 1127-1129.
- Hedges, V.J., Blowey, R.W., Packington, A.J. and Green, L.E. 2000. A longitudinal field study of the incidence and location of specific causes of Lameness on claw health in dairy cows and the effect of biotin supplementation. ISVEE, Colorado, August 2000.
- Holzhauser, M., Bartels, C.J., van den Borne, B.H. and Van Schaik, G. 2006. Intra-class correlation attributable to claw trimmers scoring common hind-claw disorders in Dutch dairy herds. *Preventive Veterinary Medicine*, 75: 47-55.
- Kiernan, J.A. 2000. *Histological and histochemical methods: theory and practice*. 3rd edition. Butterworth/Heinemann, Oxford. Pp: 111-112.
- Mason, C. and Offer, J. 2007. Preventing lameness in dairy cows, hoof lesions, their identification, treatment, management and prevention, Technical Note, TN599, The Scottish Agricultural College 2007, West Mains Road, Edinburgh EH9 3JG.
- McLennan, M.W. 1988. Incidence of lameness requiring veterinary treatment in Queensland. *Australian Veterinary Journal*, 65: 144-147.
- Montoya, D. 2006. Laminitis in dairy cattle. Retrieved from Internet: Hoof-it Bovine.
- Read, D.H., Walker, R.L., Hird, D.E., Mass, J.P. and Berry, S.L. 2010. Footwarts of cattle. California Veterinary Diagnostic Laboratory System. Retrieved from internet <http://shop.thecattle.com/listing/2/book-shop/30/beef-production/Bomin>.
- Russell, A.M., Rowlands, G.J., Shaw, S.R. and Weaver, A.D. 1982. Survey of lameness in British cattle. *Veterinary Record*, 111: 155-160.
- Shearer, J.K. and van Amstel, S.R. 2009. Toe lesions in dairy cattle. 46th Proceedings Florida Dairy

- Production Conference, Gainesville, April 28, 2009.
- Sogstad, A.M., Fjeldaas, T., Osteras, O. and Forshell, K.P. 2005. Prevalence of claw lesions in Norwegian dairy cattle housed in tie stalls and free stalls. *Preventive Veterinary Medicine*, 70: 191-209.
- Somers, J.G., Frankena, K., Noordhuizen-Stassen, E.N. and Metz, J.H. 2003. Prevalence of claw disorders in Dutch dairy cows exposed to several floor systems. *Journal of Dairy Science*, 86: 2082-2093.
- Tadich, N., Flor, E. and Green, L.E. 2010. Association between hoof lesions and locomotion score in 1098 unsound dairy cows. *The Veterinary Journal*, 184(1): 60-65.
- Tranter, W.P. and Morris, R.S. 1991. A case study of lameness in three dairy herds. *New Zealand Veterinary Journal*, 39: 88-96.
- Wells, S.J., Trent, A.M., Marsh, W.E., Williams, W.B. and Robins, R.A. 1995. Some factors associated with clinical lameness in dairy herds in Minnesota and Wisconsin. *Veterinary Record*, 136: 537-540.