www.roavs.com EISSN: 2223-0343
RESEARCH OPINIONS IN ANIMAL & VETERINARY SCIENCES

Histological study of the scrotum in rams

Saleem Abdullah Sofi

Department of Theriogenology, Physiology and Anatomy, Faculty of Veterinary Medicine, University of Duhok, Kurdistan Region, Iraq

Abstract

This study was conducted on skin samples from the proximal and distal part of scrotum of 20 rams during summer and winter season of 2011. All samples were fixed in 10% neutral buffer formalin and stained with Hematoxylin and Eosin. The results showed that the scrotum in rams consisted of epidermis and dermis. The epidermis was further composed of stratified keratinized squamous epithelium, stratum basele, stratum spinosum, stratum granulosum and stratum corneum. The thicknesses of the epidermis were thin in the proximal portion and thick in distal portion during summer and winter season. The dermis layer contained sweat glands, sebaceous glands and hair follicles. The sweat glands of the scrotum in rams of different areas were present in two forms i.e., rounded and tubular shape. The sweat glands were more present in the proximal portion of scrotum and larger than the distal portion during summer seasons. While in winter season, the sweat glands were very low in all portions of scrotum. The sweat glands of summer season were larger than the winter season. The sebaceous glands did not differ during summer and winter season. These results showed that structurally there is a substantial difference in layers of skin of the scrotum rams between different regions and seasons of years.

Keywords: Rams; scrotal histology; sweat glands; season

To cite this article: Sofi SA, 2012. Histological study of scrotum in rams. Res. Opin. Anim. Vet. Sci., 2(8), 459-463.

Introduction

The scrotum is an abdominal diverticulum and its function is to protect the testicles (Kastelic et al., 2000). In small ruminants, scrotum is long and pendulous, may not exceed the level of the tibio-tarsal joints, and the skin is abundantly covered with hair. The scrotal skin is thin, flexible and intimately attached to the tunica dartos (Getty, 1986; Dyce et al., 2004). Epidermis has a thickness variable, being composed of stratified squamous epithelium composed of several layers (Dellman & Brown, 1982; Banks, 1993; Gartner & Hiatt, 1993; Schaller, 1999; Frandson et al., 2003). The sebaceous glands are located in a region formed by the hair follicle and the skin surface by the muscle arrector pili, and their ducts open into the interior of hair follicles (Frandson et al., 2003). Its oily secretion is lubricative and keeps the skin water proof, favours the spread of sweat and slows the bacterial growth (Dyce et al., 2004).

The sweat glands, in a vision generally can be distinguished into two kinds, apocrine sweats that eliminate hair follicles, and the eccrine glands, which secrete directly onto the surface of skin. The apocrine glands are the most predominant and its secretion is important in saline metabolism and regulation of temperature. Already eccrine glands play a minor role, performing only the temperature control (Dyce et al., 2004). In cattle, the volume and the area of sweat glands per unit surface area of skin is the largest scrotal skin than other areas of the body. With raised temperature, the scrotum is distended, reducing the thickness of the skin, (Blazquez et al., 1988). The sweat glands of scrotum are larger and produce more sweat than those of any other part of the body (Bohoroues & Godinho, 1992). These glands can produce five times more sweat than those of other skin regions in response to a rise in environmental temperature (Robertshaw & Vercoe, 1980).

Corresponding author Saleem Abdullah Sofi, Department of Theriogenology, physiology and anatomy, Faculty of Veterinary medicine, University of Duhok, Kurdistan region - Iraq

Rams exhibit seasonal fluctuations in sexual behaviour, hormonal activity and gametogenesis and also in testicular weight and volume (Ortavant et al., 1988). The changes in environmental conditions have been reported to bear significant effect on sexual activity and seminal attributes (Thatcher and Hansen, 1993). The cyclic changes in pituitary and testicular activity in seasonally breeding mammals in temperate climates are prompted by changes in photoperiod, nutrition, social interactions and temperature (Bronson and Heideman, 1994; Farooq and Al-Kassab, 2009).

This work aimed to evaluate the histological aspects of scrotal skin in rams in different seasons and region of scrotum.

Materials and Methods

This study was carried out on the skin samples of the proximal and distal part of scrotum from 20 rams in a local abattoir in Duhok Governorate, during the summer and winter seasons of year 2011. All rams were more than two years which was determined before slaughter by dental examination (Wilson and Durkin 1984). Sexual maturity was confirmed by spermatozoa in the tail of the epididymis, and by normal spermatogenesis in histological sections of the testes. All samples were fixed in 10% neutral buffer formalin container for histological study, routinely processed and embedded in paraffin wax. Sections were cut at 5µm thickness and were stained with Hematoxylin and Eosin (H&E) as described by Luna (1968). The samples were examined under the light microscope.

Results

The results showed that the skin of the scrotum in rams consisted of epidermis and dermis containing sweat and sebaceous glands. The epidermis was composed of stratified keratinized squamous epithelium and stratum basale, with cylindrical cells arranged in a single layer moulded and contain large nucleus. The stratum spinosum is irregularly polygonal, and the cells are often separated by narrow and translucent clefts. These clefts are spanned by spine-like cytoplasmatic extensions of the cells which interconnect the cells of this layer. Spines of cells meet end-to-end or side-to-side and are attached to each other by desmosomes that form intercellular bridges. The stratum granulosum contained flattened cells with cytoplasm rich in granules. The stratum corneum was greatly reduced, as a thin ribbon, comprising dead and keratinized cells (Fig. 1).

The thickness of the epidermis of the scrotum in ram, varies according to the region of scrotum: thin in the proximal portion and thick in distal portion during summer and winter season respectively (Fig. 2-5). In the middle portion of scrotum, no difference was found in the thickness of epidermis. The dermis layer contained sweat glands, sebaceous glands and hair follicles. The sweat glands of the scrotum in rams of different area had alveolar structures. The excretory ducts were formed by a single layer of cubic cells in the follicles. The luminal surface of these glands have been found in clusters or vesicles and some of them present are in forms of rounded or some other tubular in shape. The sweat glands were more present in the proximal portion of scrotum and larger than the distal portion during summer season (Fig. 2 & 3), while during winter season, the sweat glands were very low from all site of scrotum compared with the summer season (Fig. 4 & 5). The sweat glands during summer season were larger than the winter season (Fig. 2 & 5). The sebaceous glands showed no difference at the different sites of scrotum during summer and winter seasons.

Discussion

The skin of the scrotum in rams consists of epidermis and dermis containing sweat and sebaceous glands. The epidermis is composed of squamous stratified keratinized epithelium, consisting of the stratum basele, with cylindrical cells arranged in a single layer and contain large nucleus. In stratum spinosum, the cells become irregularly polygonal and attached to each other by desmosomes that form intercellular bridges. The stratum granulosum contained flattened cells with cytoplasm rich granules. This result agreed with the other reports domestic species (Dellman & Brown, 1982; Banks, 1993; Gartner & Hiatt, 1993; Schaller, 1999).

The thickness of the epidermis of the scrotum rams during winter seasons is more in the distal than the proximal part (Banks, 1993; Gartner & Hiatt, 1993; Schaller, 1999). Aline et al. (2010) discovered that the thickness of the epidermis of the scrotum goats, regardless of the setting scrotal, increased gradually from proximal to distal.

The sweat glands of the scrotum rams of different sites presented alveolar structures and simple type apocrine in number of follicles by one or two, with their excretory ducts formed by a single layer of cubic cells in the follicles and leading to follicles as reported in the literature (Kolb, 1987; Banks, 1993; Gartner & Hiatt, 1993). The luminal surfaces of these glands have clusters or vesicles (Banks, 1993).

In our results, the sweat glands were more in number in the proximal portion of scrotum. Moreover, they were larger than the distal portion during summer seasons while in winter season, the sweat glands were very low in number and smaller in size. Blazquez et al. (1988) concluded that within the scrotum, there was a

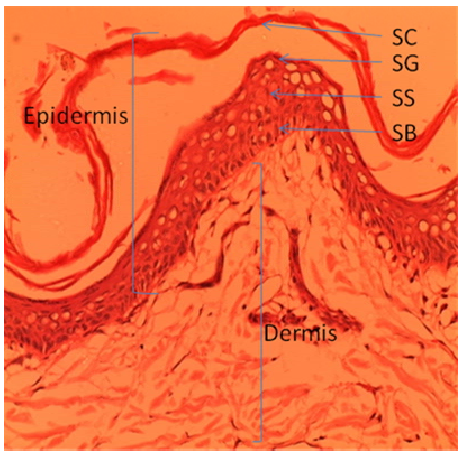

Figure 1: Micrograph of the skin of scrotum in ram showing the epidermis and dermis. The epidermis contain stratum basales(SB), stratum spinosum (SS), stratum granulosum(SG) and stratum corneum(SC) (H & E 100 X).

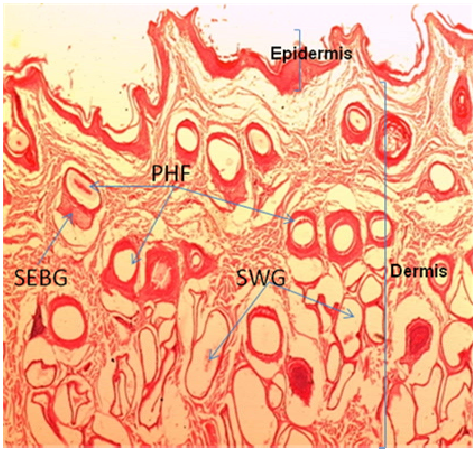

Figure 2 : Micrograph of the skin proximal region of the scrotum in ram during summer season showing the epidermis and dermis. The dermis contain sweat glands (SWG), Sebaceous glands (SEBG). Primary hair follicles (PHF) (H & E 40 X).

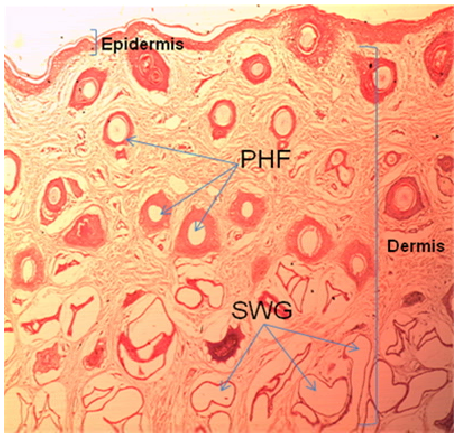

Figure 3 : Micrograph of the skin proximal region of the scrotum in ram during summer season showing the epidermis and dermis. The dermis contain sweat glands (SWG) and Primary hair follicles (PHF) (H & E 40 X).

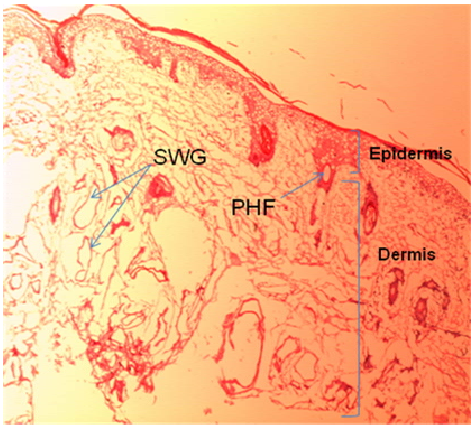

Figure 4 : Micrograph of the skin distal region of the scrotum in ram during summer season showing the epidermis and dermis. The dermis contain sweat glands (SWG) and Primary hair follicles (PHF) (H & E 40 X).

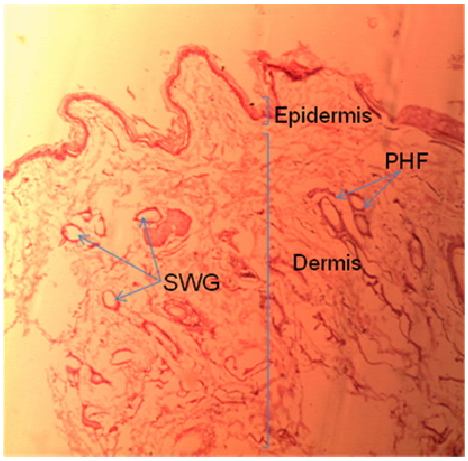

Figure 5 : Micrograph of the skin proximal region of the scrotum in ram winter season showing the epidermis and dermis. The dermis contain sweat glands (SWG) and Primary hair follicles (PHF) (H & E 40 X).

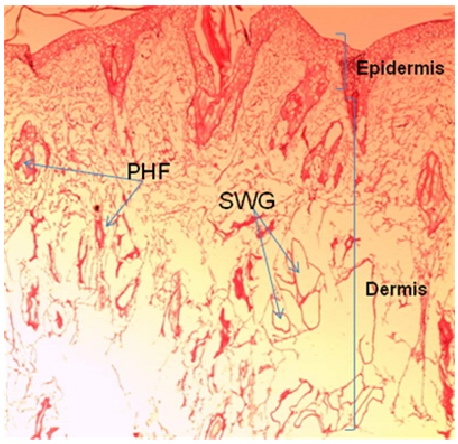

Figure 6 : Micrograph of the skin distal region of the scrotum in ram winter season showing the epidermis and dermis. The dermis contain sweat glands (SWG) and Primary hair follicles (PHF) (H & E 40 X).

gradient in sweat gland volume, increasing from proximal to distal parts of the scrotum in bull. These glands can produce five times more sweat than those of other skin regions in response to a rise in environmental temperature (Robertshaw & Vercoe, 1980). The heat loss by evaporation from the skin is directly related to the extent of sweat glands (Kolb, 1987). Our results disagreed with findings of other reports (Purohit et al., 1985; Vogler et al., 1993; Kastelic et al., 1996). These gradients in sweat gland size and scrotal temperature may reflect the ability of the scrotum to cool specific parts of the testes more than others. In the bull, the part of the testis, nearest to the largest glands is the tail of the epididymis, where the spermatozoa are stored. An increase in the storage temperature of spermatozoa, before insemination, has been shown to result in increased embryonic death (Burfening & Ulberg, 1968) so adequate thermoregulation of the epididymal tail is important. However, whether this region requires to be cooled more than the seminiferous tubules is open to debate since elevated testicular temperature has been shown to damage the seminiferous tubules.

An alternative hypothesis is that the scrotal sweat gland gradient constitutes a variable cooling capacity of the scrotum depending on testicular descent. In hot environments, when the testes are fully descended, they would be next to the largest sweat glands. Direct heat loss from the testes would be increased due to the increased evaporative cooling effects of sweating. This would permit greater cooling of the incoming arterial blood as a result of increased heat exchange at the pampiniform plexus. This hypothesis agrees with our result that the proximal portion of scrotum contain more sweat glands than the distal portion. Our results agreed with the findings of Kastelic et al. (1996) who concluded that scrotal surface temperature in bulls at 25°C was greater than at 15 °C.

The control over testicular temperature may therefore, not only be involved the degree of tunica dartos contraction and the number of sweat glands, but may also be influenced by the variable sweat gland density in the scrotum.

References

Aline S.N., Miguel C.F., Antonio A.N.J. and Ana L.A.S. 2010. Scrotum histological description in native goats from Piaui State, according to scrotal bipartition level. Rural Science, Santa Maria, Rural Science, Santa Maria. Pp: 1808-1813.

Banks, W.J. 1993. Applied Veterinary Histology. 3rd ed. Westline Industried Prive, St. Louis Missouri. Pp:658.

Blazquez, N.B. Mallard, G.J. and Wedd, S.R. 1988. Sweat glands of the scrotum of the bull. *Journal of Reproduction and Fertility*, 83:673 - 677.

Bohoroues, M.G.A. and Godinho, H.P. 1992. Irrigation blood of the scrotum zebu, Bos indicus. *Brazilian Archive of Veterinary Medicine and Animal Science*, 44: 121-127.

Bronson, F.H. and Heideman. 1994. Seasonal regulation of reproduction in mammals. In: Knobil, E., Neil, J.D. (Eds) Physiology of Reproduction, vol.2, 2nd Ed., Raven Press New York.

Burfening, P.J. & Ulberg, L.C. 1968. Embryonic survival subsequent to culture of rabbit spermatozoa at 30°C and 40°C. *Journal Reproduction and Fertility*, 15: 87-92

Dellmann, H.D. and Brown, E.M. 1982. Female reproductive system. In: Text Book of Veterinary Histology. Lea & Febiger. P:397.

Dyce, K.M., Sack, W.O. and Wensing, C.J.G. 2004. Text Book of Veterinary Anatomy. 3rd Ed. W.B. Saunders, USA. P: 811.

Farooq, T.J. and Al-Kassab A.O. 2009. Effect of seasonal variation on physical and biochemical properties of local hamdani rams semen in Erbil region. *Mesopotamia journal of Agriculture*, 27: 316-1815.

Frandson, R.D. Wilke, A.D. and Fails, W.L. 2003. Anatomy and Physiology of Farm Animals, 6th Ed. Blackwell. P: 454.

Gartner, L.P. and Hiatt, J.L. 1993. Color Atlas of Histology. 2nd Ed. Lippincott, Williams & Wilkins, Baltimore, P: 322.

Getty, R. 1986. Anatomy of domestic animals. Sisson / Grossman. 5th Ed. W.B. Saunders Company. pp: 1134.

Kastelic, J.P., Cook, R.B. and Coulter, G.H. 2000. Scrotal/testicular thermoregulation in bulls. In: Chenoweth, P.J. (ed.), Topics in Bull Fertility. International Veterinary Information Service, http://www.ivis.org.

Kastelic, J.P., Cook, R.B., Coulter, G.H., Wallins, G.L. and Entz, T. 1996. Environmental factors affecting measurement of bovine scrotal surface temperature with infrared thermography. *Animal Reproduction Science*, 41: 153-159.

Kolb, E. 1987. Veterinary Physiology. 4ed. Rio de Janeiro: Guanabara-Koogan. P: 636.

Luna, L.G. 1968. Manual of histologic staining methods of the Armed Forces Institute of pathology. 3rd Ed. McGraw Hill Book company. P:34.

Luna, L.G. 1968. Manual of histological staining methods of the Armed Forces Institute of pathology 3rd Ed. McGraw Hill Book Company. P: 34.

Ortavant, R., Bocquier, F., Pelletier, J., Ravault, J.P., Thimonier, J. and Volland-Nail, P. 1988. Seasonality of reproduction in sheep and its control by photoperiod. *Australian Journal Biological Sciences*, 41: 69–85.

Purohit, R.C., Hudson, R.S., Riddel, M.G., Carson, R.L., Wolf, D.F. and Walker, D.F. 1985. Thermography of the bovine scrotum. *American Journal of Veterinary Research*, 46: 2388-2392.

Robertshaw, D. 1980. Concepts in adaptation animals: thermoregulation of the goat. Tucson. Proceedings, Seoltsdale. Pp: 395-397.

Robertshaw, D. and Vercoe, J.E. 1980. Scrotal thermoregulation of the bull. *Australian Journal Agriculture Research*, 31: 401-407.

Schaller, O. 1999. Veterinary anatomical nomenclature illustrated. New York: Manole, pp: 614.

Thatcher, W.W. and Hansen, P.J. 1993. Environment and Reproduction In. Reproduction in Domesticated Animals Calking (Ed.). Elsevier Science Publishers, B.V. New York.

Vogler, C.J., Bame, J. H., Dejarnette, J.M., Mcgilliard, M.L. and Saacke, R.G. 1993. Effects of elevated testicular temperature on morphology characteristics of ejaculated spermatozoa in the bovine. *Theriogenology*, 40:1207-1219.

Wilson, R.T. and Durkin, J.W. 1984. Age at permanent incisor eruption in indigenous goats and sheep in semi-arid Africa. *Livestock Production Science*, 11:451-455.