RESEARCH OPINIONS IN ANIMAL & VETERINARY SCIENCES

ISSN 2221-1896 (PRINT) www.roavs.com ISSN 2223-0343 (ONLINE)

Ultra-structure of adipocytes in the digital cushion of ostrich (*Stuthio Camelus*) foot pad

Amira Eid Derbalah

Department of Histology and Cytology, Faculty of Veterinary Medicine, Alexandria University, Egypt

Abstract

The ultra-structural examination of adipocytes in the digital cushion of ostrich foot pad was performed to reveal the structural adaptation of adipocytes and elastic fibers of digital cushion to accommodate with fast movement of this unique bird. Two types of adipocytes were found, the first type was typical signet ring cells which had large fat droplets whose dimension dwarfed the cell organelles. The second type was diffused form with oval shaped adipocytes. Microfibillar aggregates of elastic fibers were closely packed and appeared to bead in a regular fashion. Some of this microfibrillar was reshaping adipocytes by making invagination of their plasma membrane.

Key words: Ostrich, Digital Cushion, Adipocytes, Elastic Fiber

Introduction

The ostrich is the largest living bird, reaching over 200 kg in weight and 2.7 m in height. It is the most specialized runner and had only two toes; the metatarsal-phalangeal joint is suspended so that the standing weight is born entirely by the digit. A further important adaptation of ostrich leg includes the presence of additional cushioning at the planter surface of digits (toes) and it is provided by paired tubular deep planter fat bodies (15×13 cm) enclosed by fibrous capsule (Shanawany and Dingle, 1999).

Fowler (1991) reported that all ratites had digital cushion similar to that of the horse. He also noted that the ostrich digital cushion was contiguous along the planter aspect of weight bearing digit, whereas, the other ratites had cushion only underneath joint. The digital cushion represents a thick layer of connective tissue in the depth of the dermis of the digital pad and frog. It serves to absorb mechanical shocks and provide support to the limb (Köng et al., 2003). The white adipose tissue that concentrates in the sole of the feet and the palms, of the hand serves as a cushion (Henrikson et al., 1997). The white adipose tissue consisted of densely packed adipose cells, capillaries and very small amount of connective tissue fibers (Zhang, 1999). Cinti (2002) found that the white adipocytes had cytoplasmic lipid arranged in single unique vacuoles, flattened nucleus and sheet like cytoplasm. The white adipose tissue was the most flexible tissue in the body because it was remodeled in size and shape by modification in adipocyte size and number (Depauw et al., 2009).

Veterinarians dealing with medical and surgical problems or propagation management of this unique flightless bird should have a basic understanding of ostrich histology of foot cushion to be able to handle ostrich safely. Therefore, this study evaluated the ultra-structure of the adipocytes in the digital cushion of ostrich foot pad.

Materials and Methods

Sixteen digital cushions were separated from eight healthy (about two years old) ostriches. Small pieces from the different parts of the fat of digital cushions were fixed in 10% neutral buffered formalin (Bancroft and Stevens, 1979) for 48 hrs then dehydrated in ascending grades of ethyl alcohol. They were cleared in xylene and embedded in three changes of paraffin. The paraffin blocks were cut at 6 µm thickness and stained by the method of Weigert's Resorcin Fuchsin for elastic fibers (Clark, 1973).

Pieces of 1 mm were cut from the skin and quickly fixed in 6% solution of phosphate buffered gluteraldehyde at 4 ºC and pH 7.4 for 6 hrs (McDowell

Corresponding author: Amira Eid Derbalah, Department of Histology and Cytology, Faculty of Veterinary Medicine, Alexandria University, Egypt

and Trump, 1976). After the initial fixation, the tissues were washed in several changes of cold (4 ºC) 0.1 M phosphate buffer every 15 minutes for 2 hrs. The tissues were then fixed in 1% solution of osmium tetroxide in cold (4 ºC) 0.1 M buffer of pH 7.2 for 2 hrs. Thereafter, they were rapidly dehydrated through ascending grades of ethyl alcohol then transferred to propylene oxide and placed in a 1:1 mixture of propylene oxide and epoxy araldite (Hayat, 1986). Semi-thin sections (1 µm) were cut firstly and stained with toludine blue and viewed with light microscope to select the suitable areas for the electron microscope examination. The ultrathin sections (60-100 nm) were cut by a glass knife with LKB microtome, and were then stained with uranyl acetate followed by lead citrate (Hayat, 1986). These sections were examined with Joel 100 cx electron microscope operating at 80 Kvs.

Results

The white adipose tissue of digital cushion of ostrich consisted of numerous adipocytes, collagen fibers, elastic fibers, few fibroblast and some blood vessels. Using the Weigert's Resorcin Fuchsin stain, several elastic fibers were seen among adipocytes (Fig. 1). By the TEM stain, two groups of adipocytes could be seen; the first group was typical signet ring adipocytes which had large lipid droplets whose dimension dwarfed the cell organelles. Nuclei of such cells were displaced to a peripheral position and were surrounded by a remnant of cytoplasm. In the vicinity of the adipocytes there was a progressive deposition of elastic fibers (Fig. 2 &3). The second group of adipocytes was scattered form or diffused form; it consisted of spherical to oval shaped adipocytes varied in size (Fig. 4 & 5). In between the adipocytes, there were microfibillar aggregates of elastic fibers which sometimes completely surrounded adipocytes (Fig. 6). These microfibrillar were closely packed and appeared to be beaded in a regular fashion (Fig. 7).

Some of these microfibrillar reshaped adipocytes by making invagination of their plasma membrane (Fig. 8). Collagen fibers were found among adipocytes with their characteristic periodic striations. Fibroblast was triangular to pyramidal in shape having several cytoplasmic processes. The cytoplasm contained numerous ribosomes, mitochondria and a pyramidal shape nucleus (Fig. 9).

Discussion

In the present study, we found that the digital cushion of ostrich consisted of numerous adipocytes, collagen fibers, elastic fibers, fibroblast and some blood vessels as reported previously (El-Gendy et al., 2011).

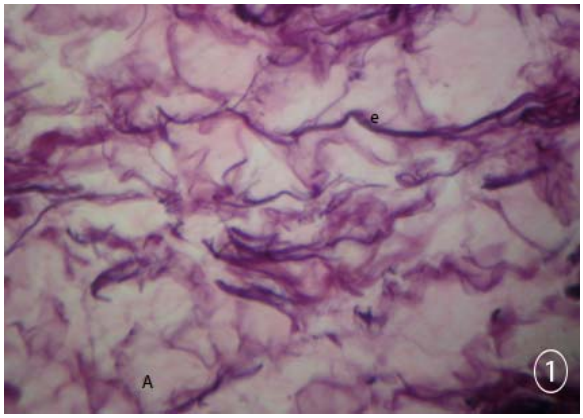

Fig. 1: Light photo micrograph of white adipose tissue of digital cushion of ostrich showing adipocytes (A) and numerous elastic fibers (e) between them. Weigert's Resorcin Fuchsin stain. (Mic. Mag. x 400).

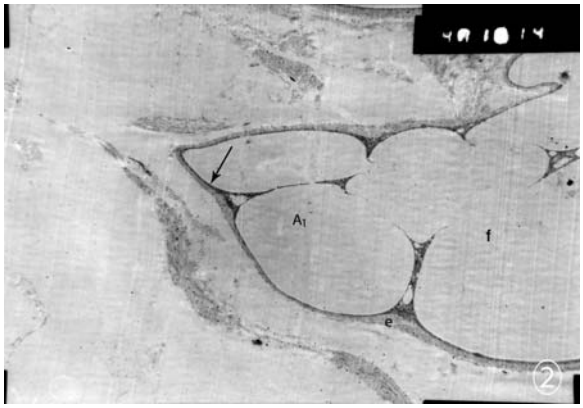

Fig. 2: Transmission electron micrograph of group1 adipocytes (A) with large fat droplet (f) and thin rim of cytoplasm (arrow) and elastic fibers (e). (Mic. Mag. x 4000).

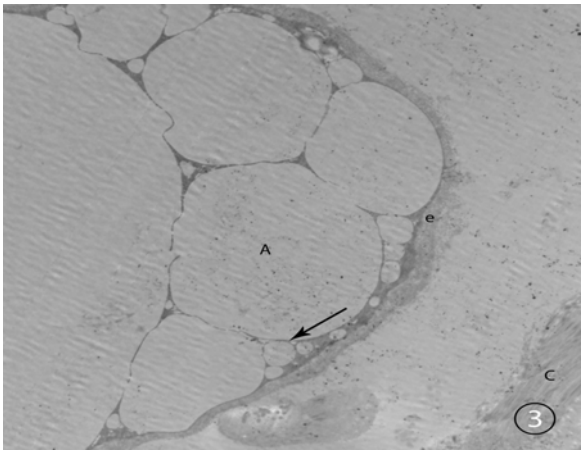

Fig. 3: Electron micrograph of group1 adipocytes (A) showing thin rim of cytoplasm (arrow), elastic fiber (e) and collagen fiber (C). (Mic. Mag. x 1500).

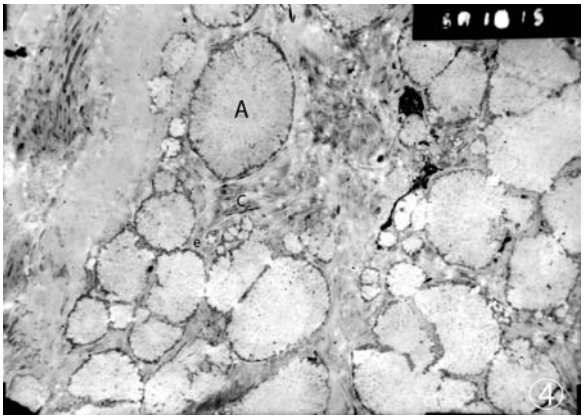

Fig.4: Transmission electron micrograph of the digital cushion showing numerous adipocytes of the second type (A2), collagen fibers(c) and elastic fiber (e). (Mic. Mag . x 5000).

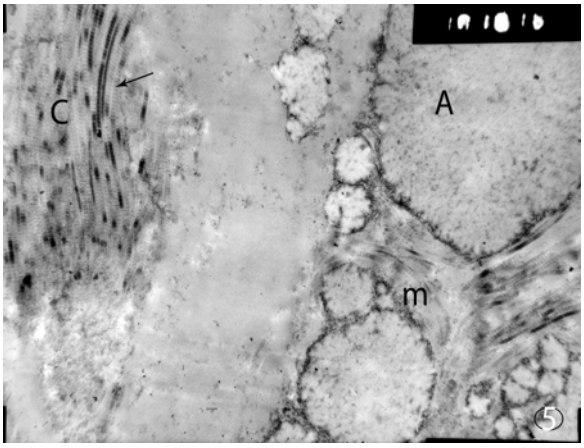

Fig. 5: Higher magnification of previous micrograph depicting second type adipocytes adipocytes (A2), collagen fibers (C) with their characteristics banding striation (arrow) and microfibrillar of elastic fibers (m) mainly in-between and around adipocytes. (Mic. Mag. X 1000).

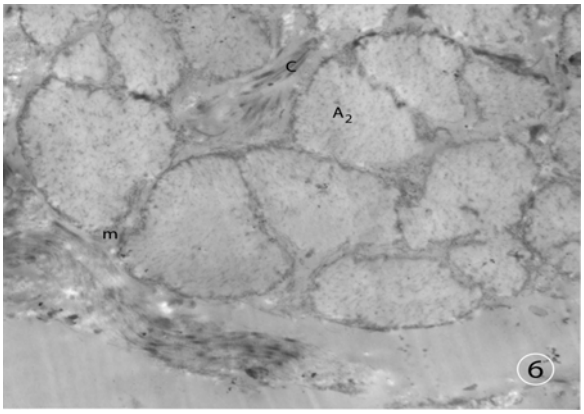

Fig.6: Transmission electron micrograph of the second type adipocytes (A2) denoting microfibrillar (m) of elastic fiber. Collagen fiber(C).(Mic.Mag.x4000).

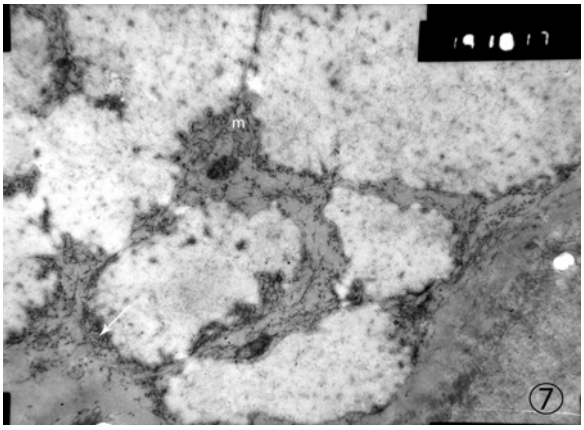

Fig.7: Electron micrograph of the second type adipocytes showing beaded appearance (arrow) of microfibrillar of elastic fiber (m). (Mic. Mag. X 15000).

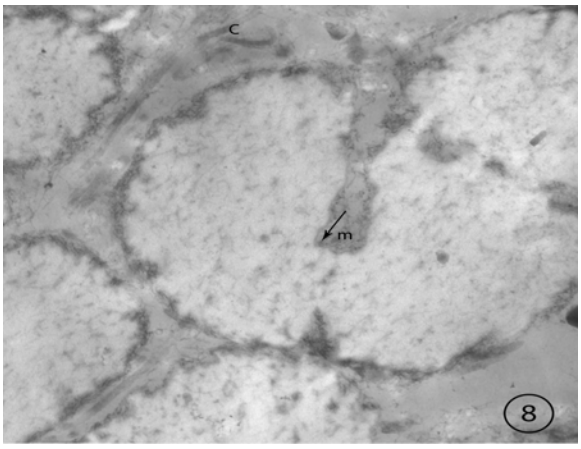

Fig.8: Transmission electron micrograph depicting the invagination of microfibrillar (m) into plasma membrane of adipocytes (arrow). Collagen fiber(C). (Mic. Mag. X 7500).

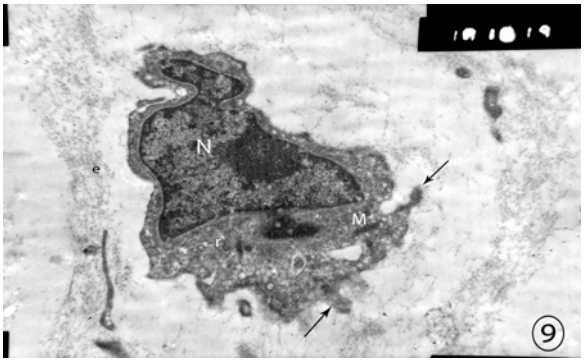

Fig.9: Transmission electron micrograph of fibroblast showing numerous ribosomes (r), mitochondria (M), cytoplasmic processes (arrow) and nucleus(N). Elastic fiber (e). (Mic. Mag. X 10000).

In the horse, Egerbacher et al. (2005) stated that the digital cushion consisted of a network of coarsely collagen bundles, myxoid tissue, fibrocartilage and the adipose tissue was scarce, while in cattle the digital cushion comprised of resilient loose connective tissue with varying amount of associated soft fat enclosed in an envelope of collagenous fibers; such cushion supports greater proportion of the body weight (Räber et al., 2004). In the current study it was observed that adipocytes had a typical signet ring appearance having single large lipid droplet and thin rim of cytoplasm. Eroschenko (2008) found that white adipocytes that have large single lipid droplet provide insulation under skin and form cushioning fat pads around organs. In the present study, the second type of adipocytes were scattered or diffuse adipocytes with different sizes having microfibrillar aggregates of elastic fibers in between them, these microfibrillar were closely packed and appeared to be beaded in a regular fashion. Kielty et al. (2002) noted that the papillary dermis of mouse contained thin perpendicular elastic fiber (alunin fiber) that merged with the microfibrillar cascade. It was also noticed in the current study that some microfibrillar reshaped adipocytes by making invagination into plasma membrane of adipocytes. It was therefore suggested that the reshaping of adipocytes by elastic fiber supported the function of adipocytes as a cushion to protect foot against concussion and absorbing shock. Foot cushion serves to absorb mechanical shock, stores and returns elastic straining energy, thus, protecting ostriches against local stress and keeping the pressure at a low level **(**Kerg, 1999; Miller-Young et al., 2002; Köng et al., 2003; Taylor et al., 2005).

Conclusion

The present study concluded that the ostrich foot pad has specially adapted digital cushion with two types of adipocytes and unique elastic fiber orientation to help this fast bird to run freely and safely.

References

Bancroft, J. and Steven, A. 1979. Theory and practice of histological techniques. 2nd (Ed.) Churchill Livingstone, Edinburg, London New York.

Cinit, S. 2002. Adipocytes differentiation and trans differentiation: plasticity of the adipose organ. *Journal of Endocrinology investigation*, 25(10):823-835.

Clark, G. 1973. Staining procedures. Baltimore. 3rd (ed.) Williams and willkins Co., P: 60.

Depauw, A., Tejerina, S., Rase, A., Keijer J, and Arnould, T. 2009. Mitochondrial (dys) function in adipocytes differentiation and systemic metabolic alteration. *American Journal of Pathology*, 175(3):927-939.

Egerbacher, M., Helmreich, M., Probst, A., Köng, H and Böck, P. 2005. Digital cushion in horses comprises coarse connective tissue,myxoid tissue and cartilage but only littleunilocular fat tissue. *Anatomy Histology and Embryology*, 34:112-116.

El-Gendy, S., Derbalah, A. and Abu EL-Magd, M. 2011. Histo-morphological study on footpad of ostrich (Stuthio Camelus) in relation to locomotion. *Journal of Veterinary Anatomy*, 4(2)1-22.

Eroschenko, V. 2008. Difiore's atlas of histology with functional correlation. 11th (ed). Lippincott. Williams & Wilkins. Pp:59-61.

Fowler, M. 1991. Comparative clinical anatomy of ratities. *Journal of zoo and wild life*, 22(1):201-207.

Hayat, M. 1986. Basic Techniques for Transmission Electron Microscope, 2nd (Ed.), Academic Press, Baltimore

Henrikson, C., Kaye, I. and Mazurkiewicz, E. 1997. Histology chapter 9.Histology N.M.S.pp:20-23.

Kerg, R. 1999. The design of soft collagenous load bearing tissue. *Journal of Experimental Biology*, 20(2): 3315-3324.

Köng, H., Macher, R., Polsterer-Heind, E., Sora, l., Hinterhofer, C., Helmreich, M. and BöCK, B. 2003. Stoβbrechende Einrichtungen am Zehenend organs des pferdes. *Veterinary Medicine Austria*, 90: 267-273.

Kielty, C., Sherratt, M. and Shuttleworth, A. 2002. Elastic fibers. *Journal of Cell Science,* 115: 2817-2828.

McDowell, A. and Trump, F. 1976. Histological fixatives suitable for diagnostic light and electron microscopy. *Archives of Pathology & Libratory Medicine*, 100: 405-415.

Miller-Young, J., Duncan, N. and Baroud, G. 2002. Material proprieties of the human calcaneal fat pad in compression: experiment and theory. *Journal of Biochemistry*, 35:1523-1531.

Räber, M., Lischer, C., Geyer, H. and Ossent, P. 2004. The bovine digital cushion a descriptive anatomical study. *The Veterinary Journal*, 167: 258-264.

Shanawany, M. and Dingle, J. 1999. Ostrich production system. FAO. Food and Agriculture organization of united Nation. Rome. Italy. Pp: 15-18.

Taylor, D., Hood, D., Potter, G., Hogan, H. and Honnas, C. 2005. Evulation of displacement of the digital cushion in response to vertical loading in equine forelimb. *American Journal of Veterinary Research*, 66:623-629.

Zhang, S.1999. An Atlas of Histology. Springer Verlag New York.Inc. Pp: 21-25.