www.roavs.com EISSN: 2223-0343
RESEARCH OPINIONS IN ANIMAL & VETERINARY SCIENCES

Radiographical, ultrasonographic and arthroscopic findings of osteochondrosis dissecans of the tarsocrural joint in horses

Mohamed B. Mostafa, Ashraf M. Abu-Seida* and Ahmed I. Abd El-Glil

Department of Surgery, Anesthesiology & Radiology, Faculty of Veterinary Medicine, Cairo University, Giza, P.O. 12211, Egypt

Abstract

Four horses (two mares and two stallions) with severe tarsal swellings were admitted to the surgery clinic at Faculty of Veterinary Medicine, Cairo University. Full case history and thorough clinical, radiographic, ultrasonographic and arthroscopic examinations were carried out on all the horses. The age of the affected animals ranged from 3-8 years. Osteochondrosis dissecans (OCD) was either unilateral or bilateral. Two animals had 0/5 degree of lameness and 2 had 2/5 degree of lameness. Two animals had bog spavin and two had bone spavin. Radiographic findings included osteochondral fragment with flattened or irregular contour of the subchondral bone surface at the intermediate ridge of tibia (2 cases), the medial malleolus of tibia (one case) or at the medial trochlear ridge of talus (one case). Ultrasonographic findings included joint effusion with anechoic fluid (synovitis), presence of echoic fragment inside the synovial fluid with acoustic shadowing and area of thickened cartilage. Arthroscopically, osteochondrosis dissecans fragments were clearly seen with congestion and bleeding in the articular surface. All horses responded well to the arthroscopic removal of the osteochondral fragments and returned to work two months post-surgery.

Keywords: Radiography; ultrasonography; athroscopy; osteochondrosis dissecans; tarsocrural joint; horses

To cite this article: Mostafa MB, AM Abu-Seida and AI Abd El-Glil, 2014. Radiographical, ultrasonographic and arthroscopic findings of osteochondrosis dissecans of the tarsocrural joint in horses. Res. Opin. Anim. Vet. Sci., 4(6): 318-322.

Introduction

Osteochondritis dissecans (OCD) is considered as a defect of endochondral ossification that may lead to fragmentation. It usually affects warm bloods and racing horses (McIlwarith et al., 1991; Van Weeren, 2006). Clinically, OCD of the tarsocrural joint is characterized by painless synovial effusion (bog spavin) with no or mild lameness, which slightly increases by hind limb flexion test (Mcllwraith, 1996; Sullins, 2002). Radiographically, there is a poor correlation between the radiographic appearance and the degree of attachment of fragments as found arthroscopically. Fragments can be mildly or firmly attached with the same radiographic appearance (McIlwraith and Foerner, 1990).

The condition involves intermediate ridge of the distal tibia most commonly (81%) followed by the lateral trochlear ridge of the talus (16%) and the medial malleolus (3%) (McIlwraith et al., 1991).

McIlwraith et al. (1991), Dik et al. (1999) and Nixon (2004) found that the radiographic abnormalities with OC/OCD are fragments, an irregular flattened contour of the subchondral bone surface, with or without subchondral radiolucencies and/or sclerosis, and sometimes secondary degenerative joint. Purely cartilaginous loose bodies are not seen using radiograph occasionally, but can be well identified using arthroscopy (Bohanon, 1999).

Ultrasonographically, OC/OCD appeared as an area of thickened cartilage, defects in the articular

***Corresponding author:** Ashraf M. Abu-Seida, Department of Surgery, Anesthesiology and Radiology, Faculty of Veterinary Medicine, Cairo University, Giza, PO 12211 Egypt.
E-mail: ashrafseida@cu.edu.eg

cartilage and appearance of subchondral bone or as an osteochondral fragment presents over an irregular subchondral bone surface (Reef, 1998; Tomlinson et al., 2000).

The osteochondral fragments appeared echoic lines or spots, usually lying in a more superficial position than the rest of the articular margin from which they are separated by anechoic gaps (Denoix, 1996; Redding, 2001).

Arthroscopy can be used as a diagnostic, prognostic and therapeutic tool in cases of osteochondrosis dissecans of the lateral trochlear ridge of the talus, distal intermediate ridge of the tibia, or tibial malleoli (Fraser and Booth, 2005; Brink et al., 2009). Stromberg and Rejno (1987) and Riley et al. (1998) reported that surgical removal and debridement of the lesions of OCD produced better results than conservative treatment in draft and race horses. McIlwraith (1990) and Sullins (2002) proved that arthroscopy facilitates exploration and visualization of the tarsocrural joint and provides extensive beneficial lavage.

The aim of this study was to record the radiographical, ultrasonographic and arthroscopic findings of osteochondrosis dissecans of the tarsocrural joint in horses.

Materials and Methods

Four horses with swollen hock joints were admitted to the surgery clinic at Faculty of Veterinary Medicine, Cairo University during the period between November 2011 and April 2013. Full case history and clinical examination were carried out. Degree of lameness was determined according to lameness grading system. All the animals were also subjected to radiographic, ultrasonographic and arthroscopic examinations.

Radiographic examination

Plain radiographic examination was carried out at a radiographic setting of 60 to 70 kVp, 10 mAs and 90 cm focal spot film distance (FFD). Dorsoplantar, lateromedial, dorsolateral plantaromedial, dorsomedial plantarolateral, flexed lateromedial and flexed dorsoplantar projections were taken according to Connie et al. (2004).

Ultrasongraphic examination

Ultrasonographic examination was performed with a real time Toshiba medical company ultrasound system, using multi frequency probes (7 MHz micro convex and 10 MHz linear probes). The ultrasound examinations were performed according to Vilar et al. (2008), with the animal bearing full weight in both longitudinal and transverse scans.

Arthroscopic examination

The horses were anesthetized by using Xylazine Hcl (1mg/ kg) as a tranquilizer, ketamine Hcl (2 mg/kg) for induction of anesthesia and triple drip (ketamine Hcl 1gm+ ½ gm xylazine+ 25 gm Guaifenesin in 500ml glucose 5%) for maintenance of general anesthesia during the operation (Knottenbel, 2006).

The Tarsus was clipped circumferentially from the proximal metatarsus to distal tibia, cleaned and draped with sterile towels immediately prior to surgery. The horse was placed in dorsal recumbency and hooves were suspended on a bar for ease of control of the degree of hock flexion.

According to McIlwraith and Foerner (1990), intra articular injection of sodium chloride 0.9% at the dorso-medial pouch of the tarsocrural joint was made. For diagnostic exploration, skin incision was made at the site of dorsomedial pouch. A conical blunt obturator was placed within the arthroscopic sheath and inserted perpendicularly to the skin surface through the fibrous joint capsule with gentle twisting motion.

The blunt obturator was replaced with the arthroscope, and the fibre optic light cable and the ingress fluid system were attached to the arthroscope and the sleeve, respectively. Rotating the arthroscope (without changing the position of arthroscope) enhanced visualization and flexing and extending the joint increased the area of visualization. The stopcock on the egress cannula was closed during visualization of the lesion or fragment.

For removal of the fragment, instrument portal was made in the dorso-medial pouch and was axial to the arthroscopic portal and usually slightly distal to the level of the arthroscopic portal (basic of tri angulations). The fragment was then elevated away using an elevator or osteotome, depending on the degree of attachment. Fragment was removed using grasper (Fig. 1A) and the defect was debrided by curettage (Fig. 1B); then the joint was washed by sodium chloride 0.9% to remove any bony debris. The skin was closed using synthetic absorbable poly galactin 910 (Vicryl) in a simple interrupted pattern. Pressure bandage was applied to the operated hock joint. The horses were given anti-titanic serum at once and systemic antibiotics and anti-inflammatory drugs for 5 days post-surgery.

Results

The age of the affected animals ranged between 3-8 years. Left hock joint was affected in two horses while bilateral affections were noticed in the other two animals. The affected animals were two mares and two stallions. Two animals had 0/5 degree of lameness while the other two had 2/5 degree of lameness. The affected animals had also bog spavin (2 cases) and bone spavin (2 cases).

Clinically, the affected animals had painless tarsal swelling especially at the medial aspect (Fig. 2A) and Spavin test was positive in two cases. Osteochodrosis dissecans was confirmed in all the animals on the basis of the followings findings.

Radiographic findings included osteochondral fragment either with flattened (Fig. 2B) or irregular contour (Fig. 3A) of the subchondral bone surface at the intermediate ridge of tibia (2 cases), the medial malleolus of tibia (one case) or at the medial trochlear ridge of talus (one case). Marked narrowing of distal intertarsal and tarsometatarsal joints and osteophyte reaction at the site of proximal intertarsal joint were also seen in two cases.

Ultrasonographic findings included joint effusion with anechoic fluid (synovitis), presence of echoic fragment inside the synovial fluid with acoustic shadowing (Fig. 3B) and area of thickened cartilage (3.5 mm). The osteochondral fragments of one case were partially separated from the parent bone and appeared as echoic lines lying in a more superficial position than the rest of the articular margin, from which they were separated by anechoic gap (Fig. 4A).

Arthroscopically, OC fragments were clearly seen with congestion and bleeding in the articular surface (Fig. 4B). All animals were treated successfully by arthroscopic removal of the osteochondral fragments with decreased tarsal swelling. The animals returned to work 2 months post-surgery.

Discussion

Osteochondrosis is characterized by a failure of normal endochondral ossification. It is characterized by abnormal cartilage within a joint that may be thickened and the deeper parts of which may become necrotic because nutrition by diffusion becomes insufficient. In the final stage, osteochondral fragments may detach and become loose or semi loose (intra-articular bodies or joint mice). In this stage, the term osteochondritis dissecans is used (Van Weeren, 2006). Osteochondrosis and OCD thus represent the same pathologic process but are at different stages of the disease. The terms often are used interchangeably (Hurtig and Pool, 1996).

Osteochondrosis is a complex disease involving interactions of inherited genetic and external environmental risk factors. Environmental factors that may play a role in disease development include nutrition, exercise, conformation and other biomechanical factors, trauma, stress response, the in utero environment, toxins, hormonal interactions and iatrogenic factors (Hurtig and Pool, 1996).

In the present study, the OC fragments were originated from distal intermediate ridge of tibia (2 horses), medial malleolus of tibia (one horse) and medial trochlear ridge of talus (one horse) as earlier recorded by McIlwraith et al. (1991).

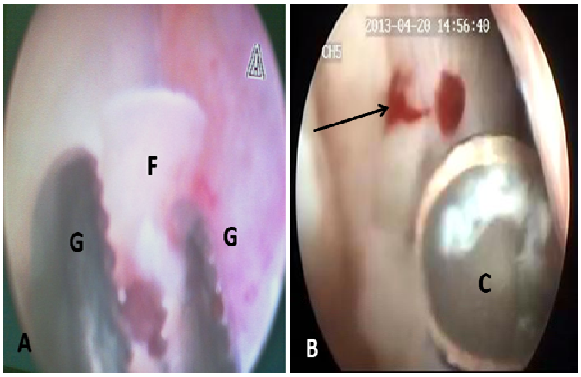

Fig. 1: (A) Digital arthroscopic image showing removal of intra articular fragment (F) using grasper (G); (B) Digital arthroscopic image showing debridement at site of the fragment (arrow) using curette (C)

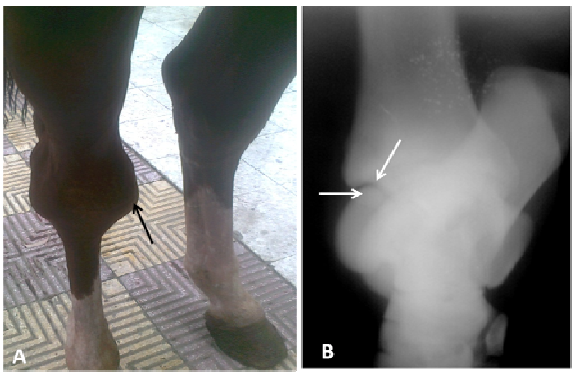

Fig. 2: (A) A 3-years old stallion showing bilateral tarsal swellings (arrow) (B) Dorsomedial plantarolateral oblique view showing osteochondral fragment from the intermediate ridge of tibia (arrows) and flattened intermediate ridge of the tibia

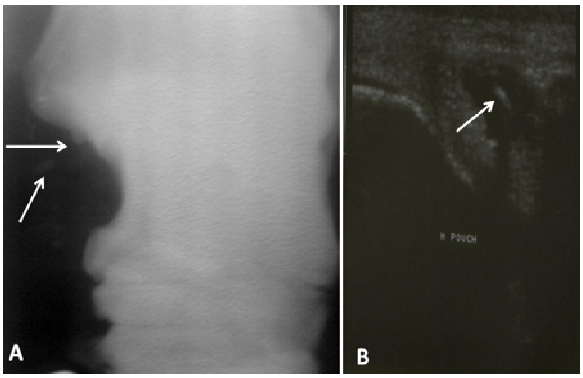

Fig. 3: (A) Dorsoplanter radiograph of the hock joint of a 4-years old stallion showing osteochondral fragment (distal arrow) originated from distal intermediate ridge of tibia which appeared irregular (proximal arrows); (B) Longitudinal ultrasonogram at dorsomedial aspect of tarsocrural joint of the same stallion showing echoic fragment (arrow) inside the anechoic synovial fluid with distal acoustic shadowing

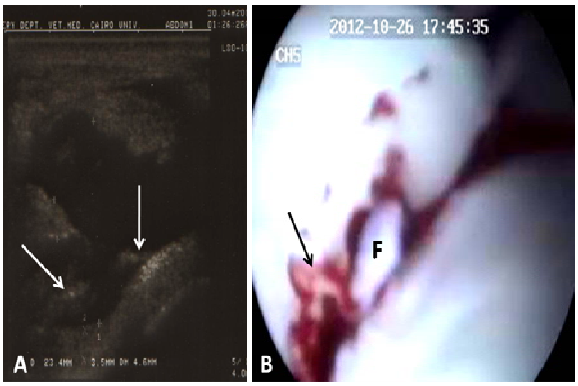

Fig. 4: (A) Longitudinal scan at dorsomedial aspect of tarsocrural joint showing area of thickened cartilage (3.5 mm) and echoic lines representing the osteochondral fragments (arrows), lying in a more superficial position than the rest of the articular margin and separated from it by anechoic gaps. (B) Digital arthroscopic image showing OC fragment (F) at intermediate ridge of tibia with congestion and bleeding within the articular surface (arrow)

Concerning the age and sex of the examined horses; OCD was recorded in animals of 3-8 years old and of both sexes. These findings coincided with McIlwraith (1996) and Sullins (2002).

DMPLO and DLPMO radiographic projections were the most helpful and important views for diagnosis of the OCD and supported the observations of Dik et al. (1999) and Nixon (2004). Ultrasonographic findings of the present study were in agreement with the results mentioned by Relave et al. (2009).

In the present study, arthroscopic examination of OCD revealed the size of the fragment, cartilage defects and bleeding and congestion of articular surface as reported earlier (McIlwraith, 1990; Relave et al., 2009).

All animals were treated successfully by arthroscopic removal of the OC fragment, curettage and debridement at the site of the removed fragment. The tarsal swelling decreased and the horses returned to the intended work after 2 months. Similar results were recorded by (Stromberg and Rejno, 1987; Riley et al., 1998).

Conclusions

Arthroscopic removal of OCD fragments at the tarsocrural joint in horses can be used successfully to treat the cases of OCD with reduced hospitalization and early return to intended work.

References

Bohanon, T.C. 1999. The tarsus. In: Equine Surgery. Auer, J.A. and J.A. Stick (Eds.). 2nd ed. Philadelphia, Pp: 848-862.

Brink, P., Dolvik, N.I. and Tverdal, A. 2009. Lameness and effusion of the tarsocrural joints after arthroscopy of osteochondritis dissecans in horses. *Veterinary Record*, 165: 709-712.

Connie, M., Cheryl, H. and Hurd, D. 2004. Practical diagnostic imaging for the veterinary technician. 3rd (ed.). C.V. Mosby, USA. pp: 132-135.

Denoix, J.M. 1996. Joints and miscellaneous tendons (miscellaneous tendons and ligaments). In: Equine Diagnostic Ultrasonography. Rantanen, N.W. and A.O. McKinnon (eds.). Baltimore, M.D. Williams and Wilkins, pp: 475-514.

Dik, K.J., Enzerink, E. and Van Weeren, P.R. 1999. Radiographic development of osteochondral abnormalities, in the hock and stifle of Dutch Warmblood foals, from age 1 to 11 months. *Equine Veterinary Journal*, 31: 9-15.

Fraser, B. and Booth, T. 2005. Equine arthroscopic surgery Part 6: Tarsocrural joint. *United Kingdom Veterinarians*, 10: 10-14.

Hurtig, M.B. and Pool, R.R. 1996. Pathogenesis of equine osteochondrosis. In: Equine formulary. Knottenbel, D.C. (Ed.). Saunders, pp: 214-217.

Knottenbel, D.C. 2006. Equine formulary. 1st ed. Saunders, pp: 220-225.

McIlwraith, C.W. 1990. Diagnostic and surgical arthroscopy in the horse. Philadelphia: Lea and Febiger, pp: 133-145.

McIlwraith, C.W. 1996. Clinical aspects of osteochondrosis dissecans. Osteochondrosis dissecans of the tarsocrural joint. In: Joint disease in the horse. McIlwraith, C.W. and Trotter, G.W. (Eds.), Philadelphia, Saunders, pp: 369-374.

McIlwraith, C.W. and Foerner, J.J. 1990. Diagnostic and surgical arthroscopy of the tarsocrural joint. In: Diagnostic and Surgical Arthroscopy in the Horse. McIlwraith, C.W. (Ed.), Lea and Febiger, Philadelphia. pp: 161-193.

McIlwraith, C.W., Foerner J.J. and Davis, D.M. 1991. Osteochondrosis dissecans of the tarsocrural joint: results of treatment with arthroscopic surgery. *Equine Veterinary Journal*, 23: 155-162.

Nixon, A.J. 2004. Management of OCD in the stifle, hock and fetlock. In: Proceedings of the 10th Annual Meeting of the Italian Association of Equine Veterinarians, SIVE, Perugia, Italy.

Redding, W.R. 2001. The use of ultrasonography in the evaluation of joint disease in horses. Part 1: Indications, technique and examination of the soft tissues. *Equine Veterinary Education*, 13: 250-259.

Reef, V.B. 1998. Musculoskeletal ultrasonography. In: Equine Diagnostic Ultrasound. Reef, V.B. (ed.). Philadelphia, PA, Saunders. pp: 39-186.

Relave, F., Meulyzer, M., Alexander, K., Beauchamp, G. and Marcoux, M. 2009. Comparison of

radiography and ultrasonography to detect osteochondrosis lesions in the tarsocrural joint: A prospective study. *Equine Veterinary Journal*, 4: 134-40.

Riley, C.B., Scott, W.M. and Caron, J.P. 1998. Osteochondritis dissecans and sub chondral cystic lesions in draft horses: A retrospective study. *Canadian Veterinary Journal*, 39: 627-633.

Stromberg, B. and Rejno, S. 1987. Osteochondrosis in the horse. I. A clinical and radiologic investigation of osteochondritis dissecans of the knee and hock joint. *Acta Radiologica Supplement Stockhholm*, 358: 139-152.

Sullins, K.E. 2002. The tarsus. In: Adams' Lameness in Horses. Stashak, T. (Ed.), Lippincott, Williams and Wilkens, Philadelphia. Pp: 930-987.

Tomlinson, J.E., Redding, W.R. and Sage, A. 2000. Ultrasonographic evaluation of tarsocrural joint cartilage in normal adult horses. *Veterinary Radiology and Ultrasound*, 41: 457-460.

Van Weeren, P.R. 2006. Etiology, diagnosis, and treatment of OC (D). *Clinical Techniques in Equine Practice*, 5: 248-258.

Vilar, J.M., Rivero, M.A., Arencibia, A., Morales, I. and Pinedo, M. 2008. Systematic exploration of equine tarsus by ultrasonography. *Anatomy, Histology, Embryology*, 37: 338-343.