www.roavs.com EISSN: 2223-0343
RESEARCH OPINIONS IN ANIMAL & VETERINARY SCIENCES

Case report

Use of parallel loop line prosthesis for management of post surgical tracheal collapse in a dog

Masaaki Katayama[1,*], Yasuhiko Okamura[1], Naoko Matsuda[1], Yuji Uzuka[1], Hiroaki Kamishina[2], Satoru Yonezawa[3,4] and Masahiro Tagawa[4]

[1]Division of Small Animal Surgery, Cooperative Department of Veterinary Medicine, Faculty of Agriculture, Iwate University, 3-18-8 Ueda, Morioka, Iwate 020-8550, Japan; [2]Division of Veterinary Clinical Radiology, Cooperative Department of Veterinary Medicine, Faculty of Applied Biological Sciences, Gifu University, 1-1 Yanagido, Gifu, Gifu 501-1193, Japan; [3]Atom Animal Hospital, 1-19-15 Tokumaru, Itabashi, Tokyo 175-0083, Japan
[4]Division of Veterinary Surgery, Department of Veterinary Medicine, Nippon Veterinary and Life Science University, 1-7-1 Kyounan, Musashino, Tokyo 180-8602, Japan

Abstract

A 12-year-old, castrated male Maltese dog was presented due to a sudden onset of tetraparesis. A ventral, extradural compressive lesion at the C_{4-5} intervertebral disk space, most compatible with an intervertebral disk extrusion was found by radiography, myelography and computed tomography. The dog received ventral slot surgery for cervical intervertebral disk hernia. After the surgery, the dog showed laboured breathing upon inspiration. Cervical and thoracic radiographs revealed severe collapse of the trachea from the fourth cervical to the second thoracic vertebra. The parallel loop line prosthesis (PLLP), which was made from the plastic optical fibre consisted of polymethylmethacrylate as the core coated by fluoropolymer as the clad, was applied as extraluminal support of the collapsed trachea. Immediately after surgery, the dog showed marked respiratory improvement except slight coughing. Two weeks after surgery, the dog could walk without difficulty and neurological status improved. Two years after the surgery, the dog has had no episodes of respiratory distress associated with the tracheal collapse. This procedure may be considered to be a surgical option for the tracheal collapse in dogs.

Keywords: Tracheal collapse; dog; parallel loop line prosthesis (PLLP)

To cite this article: Katayama M, Y Okamura, N Matsuda, Y Uzuka, H Kamishina, S Yonezawa and M Tagawa, 2014. Use of parallel loop line prosthesis for management of post surgical tracheal collapse in a dog. Res. Opin. Anim. Vet. Sci., 4(1), 63-68.

Introduction

Tracheal collapse is an obstructive airway disease primarily encountered in small breed dogs, which most commonly affects the trachea in the region of the thoracic inlet (Buback et al., 1996). Severity of clinical signs depends on the degree of obstruction of the tracheal lumen. Medical therapy is initially recommended and results in long-term resolution of clinical signs in >70% of affected dogs (White and Williams, 1994). If appropriate medical therapy does not produce satisfactory results, surgical intervention needs to be considered. Recently, endotracheal stenting therapy has been reported in dogs, which is minimally invasive and may easily relieve even intrathoracic tracheal collapse (Sun et al., 2008). However, the frequent occurrence of various complications and the cost related to endotracheal stenting may prevent it

Corresponding author: Masaaki Katayama, Division of Small Animal Surgery, Cooperative Department of Veterinary Medicine, Faculty of Agriculture, Iwate University, 3-18-8 Ueda, Morioka, Iwate 020-8550, Japan. Tel/Fax: +81-19-621-6208

from routine uses in small animal practice (Sun et al., 2008). Currently, extraluminal prostheses placement is recognized as a preferred technique for surgical repair of tracheal collapse. Although total ring prosthesis (TRP) and spiral ring prosthesis (SRP) have been reported to yield good clinical outcomes (Hobson, 1976; Fingland et al., 1987a; Fingland et al., 1987b; White, 1995; Buback et al., 1996; Ayres and Holmberg, 1999), these prostheses may have the potential of granulation tissue formation and can induce tracheal necrosis due to the excessive dissection of the trachea at implantation (Kirby et al., 1991). Yonezawa et al. (2003) developed newly designed parallel loop line prosthesis (PLLP) as an extraluminal support of collapsed trachea in dogs to ameliorate these disadvantages of the above prosthesis. In this report, we describe successful surgical management using PLLP for post surgical tracheal collapse in a dog.

Case study

A 12-year-old, 5.5-kg castrated male Maltese dog was referred to the Iwate University Veterinary Teaching Hospital suffering a sudden onset of tetraparesis. The dog had been treated with predonisolone (0.5mg/kg, PO, SID, Predonisolone「Takeda」®, Takeda, Osaka, Japan) by a referring veterinarian. Enalapril (0.5mg/kg, PO, SID, Enacard®, Zenoaq, Fukushima, Japan) had also been used to treat mild mitral valve regurgitation. At initial presentation, the dog was alert and nonambulatory in lateral recumbency. Physical examination revealed moderate cardiac murmur (Levine classification: III/VI). No clinical signs associated with respiratory diseases such as dyspnea, coughing, cyanosis were noted. Blood examination including; complete blood count, electrolytes and biochemical profile was performed and showed no abnormalities except increases of alanine transaminase (293.7IU/L, reference range: 0-130IU/L) and alkaline phosphatase ALP (3260.9IU/L, reference range: 0-200IU/L). Neurological examination revealed loss of proprioceptive placing responses in both thoracic and pelvic limbs. Thoracic limb reflexes were weak and pelvic limb reflexes were elicited normally. Deep pain sensation was present in all limbs. Cranial nerve evaluation was normal. The result of neurological examination suggested a focal lesion localized to the cervical spinal cord. Cervical and thoracic radiographs revealed no specific abnormalities (Fig. 1). The dog was anesthetized and evaluated by radiography, myelography and computed tomography. A ventral, extradural compressive lesion at the C_{4-5} intervertebral disk space, most compatible with an intervertebral disk extrusion was found. The dog recovered uneventfully from anesthesia without respiratory difficulty. The dog was maintained with predonisolone (0.5mg/kg, PO, SID, Predonisolone「Takeda」®, Takeda, Osaka, Japan) until the day of surgery.

On day 8, ventral slot procedure was performed to decompress the spinal cord. During the surgery, cefmetazole (25 mg/kg, IV, q8h, Cefmetazon®, Daiichi Sankyo, Tokyo, Japan) was given. Prednisolone (1 mg/kg, SC, q24h, Predonisolone「KS」®, Kyoritsu, Tokyo, Japan) for the prevention of spinal cord inflammation and butorphanol (0.4mg/kg, IV, q6h, Vetrphale®, Meiji Seika, Tokyo, Japan) for analgesia were also given. The dog was administered a balanced electrolyte solution (acetated Ringer's solution; 5-10 mL/kg/h). After extubation, the dog showed labored breathing upon inspiration. The dog was temporarily maintained in the oxygen cage. Aminophylline (6mg/kg, IV, q12h, Neophyllin®, Eisai, Tokyo, Japan) was administered and butorphanol (0.4mg/kg, IV, q6h) was continued as cough suppressant. Six hours later, the dog deteriorated and was intubated with propofol and maintained with 100% oxygen and sevoflurane. Methylprednisolone (15 mg/kg, IV, q12h, Solu-medrol®, Pfizer, Tokyo, Japan) was administered to prevent respiratory tract inflammation. Two hours later, the dog became relatively stable and was extubated. After extubation, the dog was maintained with oxygen mask. The dog was administered a maintenance fluid at 3 mL/kg/h (Soldem 3A®; Terumo, Tokyo, Japan). On day 9, cervical and thoracic radiographs revealed severe collapse of the trachea from the fourth cervical to the second thoracic vertebra (Fig. 2). Without the mask oxygenation, the dog could not maintain SpO_2 more than 95%. At this point, surgical correction of the tracheal collapse with PLLP was elected on day 10.

The PLLP was made from the plastic optical fiber (diameter: 1mm, ESKA®, Mitsubishi Rayon, Tokyo, Japan) which consisted of polymethylmethacrylate (PMMA) as the core coated by fluoropolymer as the clad. For PLLP preparation, short thread pins (diameter 1.2mm) were alternately inserted in a cylindrical wooden bar at the intervals of about 15mm in two rows. The diameter of the bar was determined to be 10mm based on the measurement of the diameter of the unaffected trachea on the radiographs taken at the initial presentation. The optical fiber was coiled around the wooden bar in a zigzag manner (Fig. 3) and immersed in boiled water for 2-3minutes. Subsequently, the coil was cooled with cold water to fix the form of the prosthesis because the plastic optical fiber has the property of thermal reversibility (Fig. 4). Then, PLLP was sterilized with formalin gas before surgery.

The dog was premedicated with butorphanol (0.2 mg/kg, IV, Vetorphale; Meiji Seika, Tokyo, Japan) and midazolam (0.3 mg/kg, IV, Dormicum®, Astellas, Tokyo, Japan). Anesthesia was induced with propofol (4 mg/kg, IV to affect, Propofol「Mylan」®, Intervet, Tokyo, Japan) and maintained with sevoflurane (Sevoflo ®, DS Pharma, Osaka, Japan) in 100% oxygen. The dog was

administered a balanced electrolyte solution (acetated Ringer's solution, 10 mL/kg/h) through a catheter placed in the cephalic vein. Antibiotic (cefmetazole, 25 mg/kg, IV, q8h, Cefmetazon®, Daiichi Sankyo, Tokyo, Japan) was administered at anesthetic induction and 2 hours later, and then continued twice a day until discharge from the hospital.

A routine ventral midline cervical approach to the trachea was performed. Caution was exercised to ensure that the recurrent laryngeal nerves and tracheal vessels were minimally disturbed and that they were not trapped between the trachea and the prosthesis. After fully cleaning with sterilized saline, PLLP was applied on the ventral surface of the trachea. Gentle cranial traction was applied to the cervical trachea for placement of the more caudal part of PLLP. Placement of PLLP was begun far enough into the thoracic inlet, approximately at the second intercostal space, and extended to the level just caudal to the larynx. PLLP was rotated 180°around the trachea to position the loop of the prosthesis on the dorsal tracheal membrane with minimum dissection of the trachea. Each loop of PLLP was fixed with at least 7-8 simple interrupted sutures by 5-0 monofilament non-absorbable suture material (Surgipro II®, Coviden, Tokyo, Japan) which was penetrated the tracheal lumen (Fig. 5). The remaining wound was closed in a routine fashion and the dog was allowed to recover from anesthesia. Postoperative cervical and thoracic radiographs revealed re-enlargement of the collapsed tracheal lumen. After recovery from the anesthesia, the dog showed marked respiratory improvement except slight coughing. On day 11, the dog was discharged from the hospital with the instruction to the owner to administer aminophylline (6mg/kg, PO, BID, Neophyllin®, Eisai, Tokyo, Japan) and cefalexine (25mg/kg, PO, BID, Cefalexine®, Nichiiko, Toyama, Japan) for 2 weeks.

At the 2-week re-evaluation, the dog had no clinical signs associated with tracheal collapse except slight coughing at excitement. Aminophylline was continued for the following 2 weeks. At this point, the dog could walk without difficulty and neurological status improved. At the 4-week re-evaluation, the owner reported the dog had no longer coughing and no respiratory difficulty at all. Two years after surgery, radiographs confirmed that the diameter of cervical trachea was normal (Fig. 6).

Discussion

Various surgical techniques have been reported in the veterinary literature for the treatment of tracheal collapse. Tracheal ring chondrotomy and plication of the dorsal tracheal membrane have been unsuccessful because of inadequate support of the tracheal cartilages or dorsal tracheal membrane (Leonard, 1971; Rubin et al., 1973).

As an intraluminal support, endotracheal stenting therapy offers a new treatment strategy and may easily

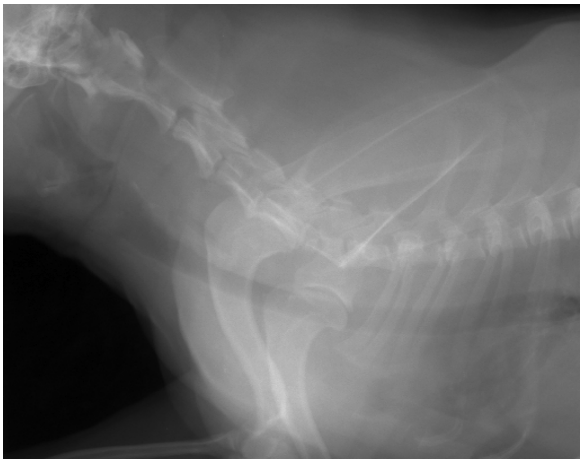

Fig 1: Cervical and thoracic radiographs at the initial presentation. Tracheal abnormalities were not noticed.

Fig 2: Cervical and thoracic radiographs on day 9. The collapse of trachea was evident from the fourth cervical to the second thoracic vertebra.

Fig 3: The optical fibre was coiled around the wooden bar (10mm in diameter) in a zigzag manner.

Fig 4: Parallel loop line prosthesis (PLLP).

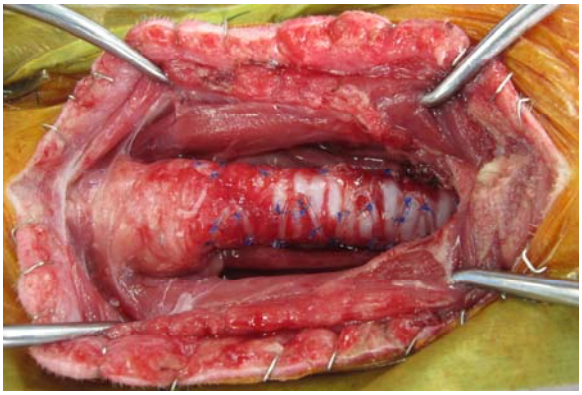

Fig 5: PLLP was fixed around trachea with simple interrupted sutures by 5-0 monofilament absorbable suture material.

Fig 6: Cervical and thoracic radiographs 2 years after PLLP treatment. Note, cervical trachea maintained normal diameter.

relieve even intrathoracic tracheal collapse, which cannot be currently treated effectively by other methods (Sun et al., 2008). However, endotracheal stenting therapy may be associated with severe complications including stent fracture, stent migration, collapse of the stent, chronic cough, pneumonia, and granuloma formation (Radlinsky et al., 1997; Hwang et al., 2001; Gellasch et al., 2002; Mittleman et al., 2004; Woo et al., 2007; Sura and Krahwinkel, 2008). Placement of stents in areas of frequent movement and application of longer prostheses may increase the risk of stent failure (Scheinert et al., 2005). In addition, the cost of the stents may prevent spreading of the technique as a primary surgical option.

Currently, extraluminal prostheses have had the most repeatable long-term success (Hobson, 1976; Fingland et al., 1987a; Fingland et al., 1987b; White, 1995; Buback et al., 1996). Placement of polypropylene TRPs (total ring prosthesis) has been shown to support a collapsed cervical trachea, which can be applied to the cranial thoracic trachea as far caudal as the 2nd or 3rd intercostal space (Hobson, 1976; Hedlund, 1991; White, 1995). Maintenance of a normal tracheal diameter was confirmed by tracheoscopy in 14 dogs at 6 month after the placement of TRPs (White, 1995). The wide size of the prostheses makes the contact area to the trachea large, which may prevent revascularization of the trachea from the surrounding tissue. Kirby et al. (1991) reported that the revascularization of the trachea was not affected by the placement of TRPs but by the degree of dissection of the trachea. It is also considered that the rigid form of the C-shaped ring might prevent the prosthesis from conforming to the trachea. Due to the lack of uniform contact, there could be areas of focal pressure with secondary tracheal necrosis (Fingland et al., 1987a; Fingland et al., 1989; Coyne et al., 1993). In smaller dogs, the collapsed tracheal rings may not conform to the over-sized C-shaped prosthesis, which causes tension to the suture (Fingland et al., 1987a). This could cause the suture to tear through the dorsal tracheal membrane resulting in recurrence of the tracheal collapse. It has been hypothesized that tracheal flexibility would be reduced as the prosthesis spanned multiple annular ligaments (Fingland et al., 1987a). An alternative to the TRP is the SRP (spiral ring prosthesis). It is thought to have less impact on tracheal flexibility, as it does not span annular ligaments over their entire circumference and its spring-like properties provide inherent flexibility (Fingland et al., 1987a; Spodnick and Nwadike, 1997). However, both TRP and SRP may have the potential of excessive granulation tissue formation because of the stiff and rough structure of their edges. In addition, SRP has rarely been used due to the necessity of excessive surgical dissection of trachea and the lack of subsequent experience.

In this report, PLLP was applied in a dog with tracheal collapse in place of these extraluminal prostheses. PLLP has been developed with the concept to incorporate the advantageous points of those prostheses. Semi-circular shaped parallel loops of the PLLP make it possible to maintain the endotracheal lumen enlarged

enough without risk of breaking, kinking or placing excessive tension on the sutures. The folded portion in a zigzag manner functioning as the joint enables flexible vertical and horizontal movement of the prosthesis. The small optic fiber used in this study had two-layered structure which consisted of PMMA (polymethylmethacrylate) coated by fluoropolymer. PMMA has been known to show high biocompatibility, reliability, relative ease of manipulation, and low toxicity (Frazer et al., 2005). PMMA has been used for bone cements, contact and intraocular lens, screw fixation in bone, filler for bone cavities and skull defects, and vertebral stabilization in osteoporotic patients (Frazer et al., 2005). In addition, the fluoropolymer surface is hydrophobic and elicits a biological response known as 'fluoropassivation' which consists of minimizing the fibrin deposition and thrombogenicity, reducing inflammatory reaction and enhancing faster neointimal healing (Guidoin et al., 1994; Xie et al., 2010; Gutiérrez-Chico et al., 2011). PLLP does not require excessive surgical dissection of trachea for implantation and it is considered to maintain tracheal flexibility. Therefore, PLLP should become an excellent biocompatible prosthesis for the repair of tracheal collapse as an alternative to TRP/SRP in dogs.

In this report, tracheal collapse was developed immediately after ventral slot procedure. The owner reported later postoperatively that the dog had an experience of slight sporadic coughing in the past. The dog may already have a low-grade collapse preoperatively, which might be associated with mitral valve regurgitation. The irritation of the trachea by the direct manipulation and retraction of the trachea and repeated inflation of the endotracheal tube cuff might have resulted in induction of tracheal collapse in this case.

Conclusion

A newly devised prosthesis, PLLP, was applied to the postoperative tracheal collapse following a ventral slot procedure in a dog. The result of PLLP placement in this dog has been favorable without any respiratory difficulties for 2 years. This procedure may be considered to be a surgical option for the tracheal collapse. Future studies with a larger number of cases are warranted to further evaluate postoperative complications and success rate of this procedure.

References

Ayres, S.A. and Holmberg, D.L. 1999. Surgical treatment of tracheal collapse using pliable total ring prostheses: results in one experimental and 4 clinical cases. *Canadian Veterinary Journal*, 40: 787-791.

Buback, J.L., Boothe, H.W. and Hobson, H.P. 1996. Surgical treatment of tracheal collapse in dogs: 90 cases (1983-1993). *Journal of American Veterinary Medical Association*, 208: 380-384.

Coyne, B.E., Fingland, R.B., Kennedy, G.A. and Debowes, R.M. 1993. Clinical and pathologic effects of a modified technique for application of spiral prostheses to the cervical trachea of dogs. *Veterinary Surgery*, 22: 269-275.

Fingland, R., DeHoff, W. and Birchard, S. 1987a. Surgical management of cervical and thoracic collapse in dogs using extraluminal spiral prosthesis. *Journal of American Animal Hospital Association*, 23: 163-172.

Fingland, R., DeHoff, W. and Birchard, S. 1987b. Surgical management of cervical and thoracic collapse in dogs using extraluminal spiral prosthesis - results in seven cases. *Journal of American Animal Hospital Association*, 23: 173-181.

Fingland, R.B., Weisbrode, S.E. and DeHoff, W.D. 1989. Clinical and pathologic effects of spiral and total ring prostheses applied to the cervical and thoracic portions of the trachea of dogs. *American Journal of Veterinary Research*, 50: 2168-2175.

Frazer, R.Q., Byron, R.T., Osborne, P.B. and West, K.P. 2005. PMMA: an essential material in medicine and dentistry. *Journal of Long Term Effects of Medical Implants*, 15: 629-639.

Gellasch, K.L., Da Costa Gomez, T., McAnulty, J.F. and Bjorling, D.E. 2002. Use of intraluminal nitinol stents in the treatment of tracheal collapse in a dog. *Journal of American Veterinary Medical Association*, 221: 1719-1723, 1714.

Guidoin, R., Marois, Y., Zhang, Z., King, M., Martin, L., Laroche, G. and Awad, J. 1994. The benefits of fluoropassivation of polyester arterial prostheses as observed in a canine model. *ASAIO (American Society of Artificial Internal Organs) Journal*, 40: M870-879.

Gutiérrez-Chico, J.L., van Geuns, R.J., Regar, E., van der Giessen, W.J., Kelbæk, H., Saunamäki, K., Escaned, J., Gonzalo, N., di Mario, C., Borgia, F., Nüesch, E., García-García, H.M., Silber, S., Windecker, S. and Serruys, P.W. 2011. Tissue coverage of a hydrophilic polymer-coated zotarolimus-eluting stent vs. a fluoropolymer-coated everolimus-eluting stent at 13-month follow-up: an optical coherence tomography substudy from the resolute all comers trial. *European Heart Journal*, 32: 2454-2463.

Hedlund, C.S. 1991. Tracheal collapse. *Problem of Veterinary Medicine*, 3: 229-238.

Hobson, M. 1976. Total ring prosthesis for the surgical correction of collapsed trachea. *Journal of American Animal Hospital Association*, 12: 822-828.

Hwang, J.C., Song, H.Y., Kang, S.G., Suh, J.H., Ko, G.Y., Lee, D.H., Kim, T.H., Jeong, Y.K. and Lee, J.H. 2001. Covered retrievable tracheobronchial hinged stent: an experimental study in dogs. *Journal of Vascular and Interventional Radiology*, 12: 1429-1436.

Kirby, B.M., Bjorling, D.E., Rankin, J.H. and Phernetton, T.M. 1991. The effects of surgical isolation and application of polypropylene spiral prostheses on tracheal blood flow. *Veterinary Surgery*, 20: 49-54.

Leonard, H.C. 1971. Surgical correction of collapsed trachea in dogs. *Journal of American Veterinary Medical Association*, 158: 598-599.

Mittleman, E., Weisse, C., Mehler, S.J. and Lee, J.A. 2004. Fracture of an endoluminal nitinol stent used in the treatment of tracheal collapse in a dog. *Journal of American Veterinary Medical Association*, 225: 1217-1221.

Radlinsky, M.G., Fossum, T.W., Walker, M.A., Aufdemorte, T.B. and Thompson, J.A. 1997. Evaluation of the Palmaz stent in the trachea and mainstem bronchi of normal dogs. *Veterinary Surgery*, 26: 99-107.

Rubin, G., Neal, T. and Bojrab, M. 1973. Surgical reconstruction for collapsed tracheal rings. *Journal of Small Animal Practice*, 14: 607-617.

Scheinert, D., Scheinert, S,. Sax, J., Piorkowski, C., Braunlich, S., Ulrich, M., Biamino, G. and Schmidt, A. 2005. Prevalence and clinical impact of stent fractures after femoropopliteal stenting. *Journal of American College of Cardiology*, 45: 312-315.

Spodnick, G.J. and Nwadike, B.S. 1997. Surgical management of extrathoracic tracheal collapse in two large-breed dogs. *Journal of American Veterinary Medical Association*, 211: 1545-1548.

Sura, P.A. and Krahwinkel, D.J. 2008. Self-expanding nitinol stents for the treatment of tracheal collapse in dogs: 12 cases (2001-2004). *Journal of American Veterinary Medical Association*, 232: 228-236.

Sun, F., Uson, J., Ezquerra, J., Crisostomo, V., Luis, L. and Maynar, M. 2008. Endotracheal stenting therapy in dogs with tracheal collapse. *Veterinary Journal*, 175: 186-193.

White, R. and Williams, J. 1994. Tracheal collapse in the dog - ia there really a role for surgery? A survey of 100 cases. *Journal of Small Animal Practice*, 35: 191-196.

White, R.N. 1995. Unilateral arytenoid lateralisation and extraluminal polypropylene ring prostheses for correction of tracheal collapse in the dog. *Journal of Small Animal Practice*, 36: 151-158.

Woo, H.M., Kim, M.J., Lee, S.G., Nam, H.S., Kwak, H.H., Lee, J.S., Park, I.C. and Hyun, C. 2007. Intraluminal tracheal stent fracture in a Yorkshire terrier. *Canadian Veterinary Journal*, 48: 1063-1066.

Xie, X., Guidoin, R., Nutley, M. and Zhang, Z. 2010. Fluoropassivation and gelatin sealing of polyester arterial prostheses to skip preclotting and constrain the chronic inflammatory response. *Journal of Biomedical Materials Research Part B: Applied Biomaterials*, 93: 497-509.

Yonezawa, S., Yajima, S., Yonezawa, R. and Kamata, S. 2003. A newly devised prosthesis for surgical treatment of tracheal collapse in dogs. (in Japanese). *Journal of Animal Clinical Medicine*, 11: 155-161.