www.roavs.com EISSN: 2223-0343
RESEARCH OPINIONS IN ANIMAL & VETERINARY SCIENCES

Experimental gastric defect reconstruction with colonic submucosal autograft in dogs

Layth ALkattan

Department of Surgery and Theriogenology, College of Veterinary Medicine, University of Mosul, Mosul-Iraq

Abstract

This study was carried out to test the efficacy of colonic submucosal patches to repair gastric defect in dogs. Under general anesthesia, a five cm square patch of colonic submucosa was used to reconstruct an experimentally induced gastric defect in twelve local breed of dogs of both sexes. Clinically, the animals showed mild deterioration in general condition, loss of appetite and abdominal pain. These signs subsided gradually during the few days after the operation. No serious intraoperative and postoperative complications were encountered. On gross and laparoscopic examination, no distinguishable differences were detected between graft and recipient stomach and only mild adhesions were detected. Histopathological examination revealed excessive granulation tissue and fibrous connective tissue with mature collagen fibres after 60 and 90 days post-surgery, respectively. In conclusion, autologous colonic submucosal graft could be used for reconstruction of experimental gastric defect in dogs.

Keywords: Colon; submucosa; autograph; stomach; dogs

To cite this article: ALkattan L, 2014. Experimental gastric defect reconstruction with colonic submucosal autograft in dogs. Res. Opin. Anim. Vet. Sci., 4(2), 107-110.

Introduction

In dogs many affections as neoplasia, hepatic disease, inflammatory bowel disorders and some drugs are common causes of gastric ulcer (Hall, 2000), which may damage gastric wall. Different reconstructive techniques have been advocated to repair defective stomach (Thompson, 1986). Various synthetic materials either absorbable or nonabsorbable polymer patch were used for repairing full thickness wall defect of the stomach (Thompson, 1986). Recently, natural materials like cellular matrix was used (Wang, 2005), or full thickness of vascularized jejunum pedicle was used to accelerated healing of defective stomach in dog (Alkattan et al., 2011). Recently, small intestinal submucosa (SIS) was used for reestablishing the continuity of the defective extensively damaged stomach (Badylak et al., 2002). In addition, the small intestinal submucosal grafts were used in animals due to the lower incidence of infection (Badylak et al., 1994). On as the other hand, leakage and uremia were exhibited after using submucosa of the colon for repairing urinary bladder defect in dogs (Alkattan, 2008). Omentum has been used as a free graft and as a vascularized omental flap to protect intestinal anastomoses (Ruffini, 1992) and for repairing the defect of bone and soft tissue in dog (Alkattan and Alkassab, 2009). The authors did not find any report concerning use of colon submucosa with omentum to repair gastric defect in dogs. Therefore, the present study was designed to investigate the feasibility of colonic submucosa for reconstruction of a large full-thickness gastric defect in dogs.

Materials and Methods

A total of 12 healthy dogs from both sex, weighing 16±0.9 kg were used in this study. All animals received humane care in compliance with the standard local guidelines. So the dogs were given standard food and free access to water. All animal experimental procedures were approved by Animals' House of the College of Veterinary Medicine, University of Mosul-Iraq. These animals were acclimatized to handling for

Corresponding author: Layth ALkattan, Department of Surgery and Theriogenology, College of Veterinary Medicine, University of Mosul, Mosul- Iraq.

7-8 days before surgery. The animals were premedicated with atropine sulphate (0.05 mg/kg, S/C) and xylazine (1 mg/kg I.M, Dutch Farm Company, Holand). Induction of general anesthesia was carried out by 1% propofol (Dong kook Company, Korea) at a dose 2 mg/kg body weight given intravenously. Anesthesia was maintained with 1% Halothane (Alebo Company, Syria) via closed system. During surgery lactated Ringer's solution (40–60 ml/kg body weight) was administered intravenously through a cannula fixed into the saphenous vein. Under aseptic conditions, the abdomen was opened via a midline linea alba incision between xyphoid cartilage and umbilicus. Then, 5-7 cm long sections of colon were harvested. The continuity of the colon was restored with an end-to-end anastomosis. The obtained fresh graft was disseminated mechanically to separate the tunica mucosa and seromuscular layers of the colon. The remaining layer i.e. tunica submucosa (Fig. 1) was prepared according to Badylak et al. (1989). The graft was rehydrated by immersion for 10 min in sterile lactated Ringer's solution at room temperature and trimmed to the dimensions slightly larger than the induced gastric defect. Experimental circular gastric defect about four cm was induced at great curvature of stomach then colonic submucosa was grafted at the defect site using 3–0 absorbable suture material in continuous pattern (Fig. 2). The repaired gastric defect was then wrapped with omentum (Fig. 3). Postoperatively, all the dogs were followed up for 3 months. All clinical data, including behaviour, health condition survival status, appetite and defecation were recorded. Laparoscopic examinations were done by laparoscopy system (Karl Stores, Germany) at 30th day post surgery. Exploratory laparotomy was done and gastric specimens from the operation site were harvested at eight and twelve weeks postoperatively. The Specimens were fixed in 10% formalin and then paraffin sections (4-6 micrometer thick) were prepared and stained for histological examination (Drury et al., 1980).

Results

All the dogs survived during the intended study period. Clinically the animals showed mild deterioration in general condition, loss of appetite and abdominal pain. These signs subsided gradually during the first few days of operation. No serious intraoperative complications were faced. Only two dogs underwent postoperative peritonitis which were treated and were excluded from experiment. Animals gained their weight and had no evidence of gastric and or intestinal perforation postoperatively. After 30 days, surgeries laparoscopic and gross finding revealed absence of generalized peritonitis, abscess formation, extensive adhesions, or free abdominal fluid in all the dogs. Moreover, upon gross examination complete healing occurred with normal serosal continuity of the stomach so, nothing to distinguish between the graft and the native stomach. Mild adhesions between stomach and viscera were, however, recorded (Fig. 4). Histopathological examination at 60 days post-surgery

Fig. 1: Photograph showing the harvested colonic submucosal autograph in a dog

Fig. 2: Photograph showing the repaired gastric defect with colonic submucosa in a dog

Fig. 3: Photograph showing the repaired gastric defect wrapped with omentum flap in a treated dogs

showed signs of healing response in the form of granulation tissue with newly formed capillaries and fibroblasts (Fig. 5). At 90 days postoperatively, fibrous connective tissues with mature collagen fibres were noted (Fig. 6).

Discussion

Intestinal submucosa is a biodegradable, commercially available, acellular, immunologically inert collagen matrix (De la Fuente et al., 2003; Hoeppner et al., 2009). Early investigations also demonstrated a possible antibacterial effect of the SIS (Sarikaya et al., 2002). In recent years, experimental studies have shown considerable success of using intestinal submucosal layer as a tissue graft in blood vessels (Hoeppner et al., 2009), ureter and tendons (Alluman et al., 2001; Alkattan, 2008). The submucosa contains active growth factors that are able to promote tissue remodeling and regenerate the tissue (Voytik-Harbin et al., 1997). In the past, colonic anastomosis showed beneficial effects of omental reinforcement at the site of anastomosis (Tocchi et al., 2000). In the present study, the use of colonic submuocosa with omental reinforcement reduced the chances of gastric leakage and incidence of peritonitis which were confirmed by laparoscopic findings. Previous study described that free omental transplant within few hours could adhere firmly to the intestinal surface on which they had been placed (Ruffini, 1992). Omentum was used both as a free graft and as a vascularized omental flap to protect intestinal anastomoses (Tocchi et al., 2000). In that study omentum was loosely wrapped around the antimesenteric surface and then tacked over the anastomosis to reinforce the anastomosis and to enhance healing (Tocchi et al., 2000). Similar findings were observed in many operations including jejunum anastomosis and gastric reconstruction with jejunum pedicles (Alkattan et al., 2011). In the current study, the use of colonic submucosa might have enhanced healing by providing the temporary strength or serving as scaffold for the immediate repair (Badylak et al., 2002). In the present study, stomach was repaired with submucosal colonic graft and wrapped with intact vascularized omental pedicle to support the healing and protect the stomach from leakage. Similar recommendations were made by Williams and Niles (2005). The enhancing of healing occurs due to the presence of some growth factors in the intestinal submucosa that stimulate growth and cell division, migration and differentiation (Soccol and Duda, 2004). Laparoscopic examination after 30 days of surgery showed no serious complications except mild adhesions with the omentum that was considered advantageous for sealing incision and might have played a role in preventing adhesion with other neighbouring organs (Hoeppner et al., 2009). Histologically, at 60 and 90 days post surgery there were proliferation of granulation tissue

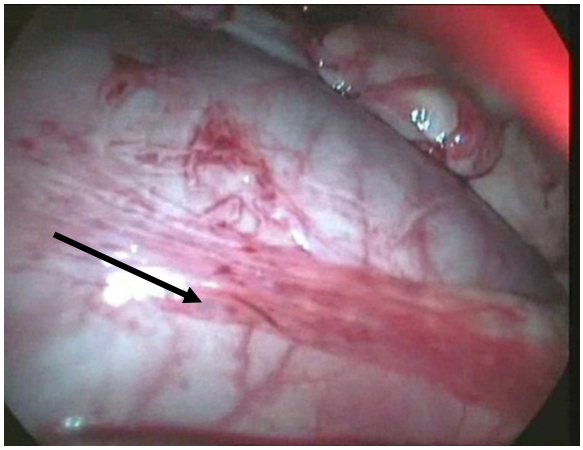

Fig. 4: Laparoscopic picture of the operative site 30 days postoperatively showed mild adhesion (arrow)

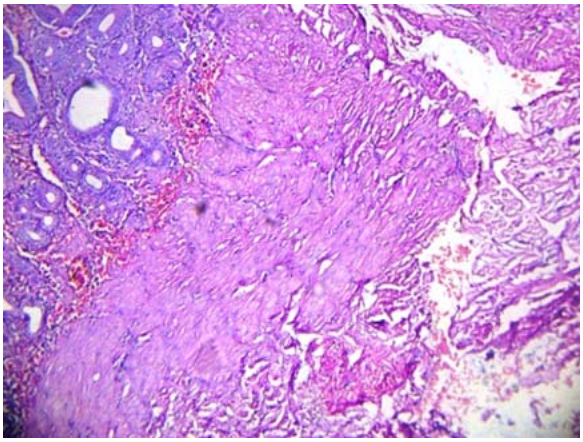

Fig. 5: Photomicrograph at 60 days after surgery showing granulation tissue, angiogenesis and inflammatory infiltration. 100 X H&E

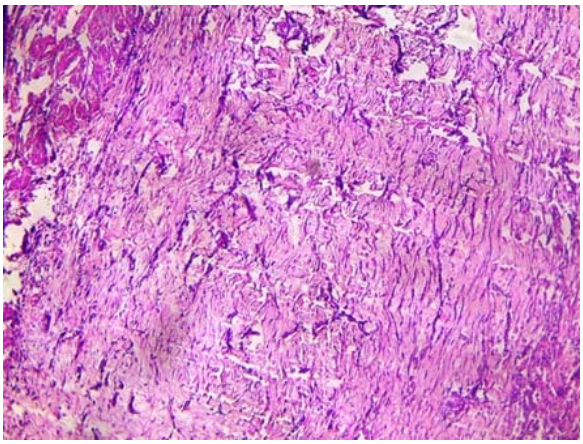

Fig. 6: Photomicrograph at 90 days after surgery showing fibrous connective tissue and mature collagen fibres. 100 X H&E

and fibroblasts. This was in agreement with McGavin and Zachary (2007). In conclusion, the free submucosal autografts could be used successfully to repair the stomach wall defect in dogs.

Acknowledgements

This study was supported by the College of Veterinary Medicine, University of Mosul, Iraq.

References

AL-kattan, L.M., Mohammad, F.M. and Bader, O.A. 2011. Gastrorrhaphy with jejunum pedicle in dogs. *Assiut Veterinary Medical Journal*, 57: 463-474.

Alkattan, L.M. and Alkassab, A.M. 2009. A comparative radiological study of experimental bone and soft tissue defect healing treated with great omentum in dogs. *Iraqi Journal of Veterinary Science*, 23: 175-179.

Alkattan, L.M. 2008. Urinary bladder defect reconstruction with autogenous colon graft in dogs. Proceeding 13th Assuit University Congress, Assuite, Egypt, 493-497.

Alluman, A.J., Mcpherson, T.B., Bardylak, S.F., Merrill, L.C., Kallkury, B., Sheehan, C.Raeder, R.H. and Metzger, D.W. 2001. Xenogeneic extracellular matrix grafts elicit a TH2-restricted immune response. *Transplantation*, 71: 1631-1640.

Badylak, S.F., Coffey, A.C. and Lantz, G.C. 1994. Comparison of the resistance to infection of intestinal submucosa. Arterial autografts versus polytetra-fluoroethylene arterial prostheses in a dog model. *Journal of Vascular Surgery*, 19: 465- 72.

Badylak, S., Kokini, K., Tullius, B., Simmons-Byrd, A. and Morff, R. 2002. Morphologic study of small intestinal submucosa as a body wall repair device. *Journal of Surgical Research*, 103: 190-202.

Badylak, S.F., Lantz, G.C., Coffey, A. and Geddes, L.A. 1989. Small intestinal submucosa as a large diameter vascular graft in the dog. *Journal of Surgical Research*, 47: 74-80.

Drury, R.A., Wallington, B. and Carlton, E.A. 1980. Histological Techniques. 5th ed. Oxford University Press, London.

De la Fuente, S.G., Gottfried, M.R., Lawson, D.C., Harris, M.B., Mantyh, C.R. and Pappas, T.N. 2003. Evaluation of porcine-derived small intestine submucosa as a biodegradable graft for gastrointestinal healing. *Journal of Gastrointestinal Surgery*, 7: 96-101.

Kropp, B.P. 1998. Small intestinal submucosa for augmentation of review preclinical studies. *World Journal of Urology*, 16: 262-267.

Hall, J.A. 2000. Diseases of the stomach. In: Ettinger S.J, Feldman E.C. (ed). Text book of Veterinary Internal Medicine: Diseases of the Dog and Cat, 5th ed., Philadelphia, Saunders, USA, pp: 1154-1168.

Hoeppner, J., Vladan, C., Goran, M., Eva, J., Wojciech, K., Weiser, H. and Ullrich, T. 2009. Small intestinal submucosa as a bioscaffold for tissue regeneration in defects of the colonic wall. *Gastrointestinal Surgery*, 13: 113-119.

McGavin, M.D. and Zachary, J.F. 2007. Pathologic Basis of Veterinary Disease. 4th ed. Mosby-Elsevier, St. Louis, Missouri.

Ruffini, E. 1992. Surgical applications of the greater omentum: critical review of the literature. *Panminerva Medicine*, 34: 135.

Robert, N.W. 2010. Complications of gastro-intestinal surgery Congress. SCIVAC BVet Med, Nottingham (UK), pp: 251-253.

Sarikaya, A., Record, R. and Wu, C.C. 2002. Antimicrobial activity associated with extracellular matrices. *Tissue Engineering*, 8: 63-71.

Soccol, A. and Duda, J. 2004. Use of small intestinal submucosa as urethral allograft. *Brazilian Journal of Urology*, 30: 327-335.

Thompson, J.S., Kampfe, P.W., Newland, J.R. and Vanderhoof, J.A. 1986. Growth of intestinal neomucosa on prosthetic materials. *Journal of Surgical Research*, 41: 484-492.

Tocchi, A., Mazzoni, G., Lepre, L., Costa, G., Liotta, G. and Agostini, N. 000. Prospective evaluation of omentoplasty in preventing leakage of colorectal anastomosis. *Disease Colon Rectum*, 43: 951- 955.

Voytik-Harbin, S.L., Brightman, A.O. and Kraine, M.R. 1997. Identification of extractable growth factors from small intestinal submucosa. *Journal of Cellular Biochemistry*, 67: 478-491.

Wang, Z.Q. 2005. Morphologic evaluation of regenerated small bowel by small intestinal submucosa. *Journal of Paediatric Surgery*, 540: 1898-1902.

Williams, J. and Niles, J. 2005. Manual of canine and feline abdominal surgery. BSAVA. 65-70

Zhang, F., Zhang, J. and Lin, S. 2003. Small intestinal submucosa in abdominal wall repair after TRAM flap harvesting in a rat model. *Plastic Reconstruction Surgery*, 112: 565-70.