

Evaluation of two techniques for management of ocular setariasis in horses

Aswathy Gopinathan¹, Kiranjeet Singh^{1*}, A.C. Saxena¹, K.L. Khurana² and Amarpal¹

¹Division of Surgery, ²Parasitologist, Polyclinic, Indian Veterinary Research Institute, Izatnagar, Bareilly (UP)-243122, India

Abstract

The present report puts on record the pros and cons of two methods of eye worm retrieval in 26 horses. Docile animals, allowing restraint, were included in group A (n=7) and aggressive animals evading head restraint were included in group B (n=19). The worm was removed by needle paracentesis at 7-8 O' clock positions of the cornea; approximately 1 mm away from the limbus under regional nerve blocks in group A. In group B, however, a 2-3mm corneal incision was made close to the limbus at 10-2 O'clock positions under general anesthesia and regional nerve blocks, to retrieve the worm. Eye ball movements could not be stopped completely in group A but in group B there were no movements of either the eye ball or the animal during surgical intervention. Higher success rate (100%) was achieved in group B as compared to group A (85.71%). Postoperative complications were minimal in both groups. Vision was restored in all the animals without corneal opacity within 15-25 postoperative days. Although removal of ocular parasite through needle paracentesis under regional nerve block analgesia is more economical and less time consuming, the nick incision under general anesthesia is preferable for the management of ocular setariasis in horses particularly in aggressive animals.

Keywords: Ocular Setariasis; horses; surgical retrieval

To cite this article: Gopinathan A, K Singh, AC Saxena, KL Khurana and Amarpal, 2013. Evaluation of two techniques for management of ocular Setariasis in horses. Res. Opin. Anim. Vet. Sci., 3(11), 407-411.

Introduction

Ocular setariasis is a disease of equine resulting from ectopic parasitism caused by *Setaria spp.*, a genus of filaroid worms (Gangwar et al., 2008). In Indian subcontinent, it occurs mostly in summer and autumn seasons when the vectors (*Anopheles peditaneniatus* and *Culex nilgircus*) are most prevalent (Mritunjay et al., 2011). The parasite is transmitted by mosquitoes through the blood stream and can be found in various organs such as heart, lung, spleen, kidney, uterus, oviduct, ovary, and urinary bladder (Varma et al., 1971). The parasite exhibits migratory behavior in unusual hosts such as horses, donkeys or human beings and immature worm can invade eye (Sreedevi et al., 2002; Tuntivanich et al., 2011) through the vascular system (Townsend, 2013). The erratic movement of the worm within the anterior chamber of the eye may cause severe irritation to the cornea causing corneal opacity, which usually ensues in blindness. Though, involvement

of the eye is commonly unilateral but bilateral occurrence is reported too (Shin et al., 2002; Buchoo et al., 2005). The best treatment of ocular setariasis is the surgical removal of the parasite (Tuntivanich et al., 2011) that can be performed under general anesthesia or regional nerve blocks. Surgical interventions used for treatment of ocular setariasis include needle paracentesis at 3 O' clock (Sreedevi et al., 2002) and nick incision at 12 O' clock position methods (Buchoo et al., 2005). Perusal of the available literature did not reveal any report concerning the comparison of the two techniques for successful retrieval of the eye worms in equine. The present report places on record the comparison of two techniques for management of ocular setariasis in horses.

Materials and Methods

Twenty six horses referred to the Institute Polyclinic with the signs of ocular Setariasis including

Corresponding author: Kiranjeet Singh, Division of Surgery, Indian Veterinary Research Institute, Izatnagar, Bareilly (UP)-243122, India.

varying degrees of corneal opacity made the material of the study. At the time of presentation, signalment, extent of lacrimation, presence of moving eye worm (Fig.1), degree of corneal opacity (Fig. 2), history of last deworming and previous treatment, if any, were recorded.

The horses presented during the study period (2012-2013) showed various signs of ocular problems including epiphora, blepharospasm, corneal opacity and even blindness. Ophthalmic examination was performed in all the cases. The anterior chamber was thoroughly examined by both lateral and retroillumination to detect the presence of worm/s inside the chamber. The corneal opacity caused by the worm was graded as mild (slightly hazy), moderate (cloudiness with visible worm) or severe (whitish cloudiness and eye worms were hard to locate). After confirmation of presence of the eye worm, considering the temperament of the animal, all the infested animals were divided into two groups. The animals with docile behavior were included in group A (n=7) and the aggressive animals resisting handling were included in group B (n=19). Five ml of tetanus toxoid was given I/M to all the animals, a day before the proposed surgery.

During pre-surgical preparations, all the horses were given 0.3% Flurbiprofen as topical non-steroidal anti-inflammatory agent (Flur®, Allergan India Private Limited) and 0.5%, Povidone-iodine as topical antiseptic solution (Betadine®, Win-Medicare, India) along with systemic non-steroidal anti-inflammatory agent flunixin meglumine (Megludyne®, Virbac Animal Health India Pvt. Ltd.) at a dose of 0.25 mg/kg b.wt given I.V.

In the animals of group A supraorbital, auriculo-palpebral and retrobulbar nerve blocks were performed using 2% lidocaine (LOX 2%®, Neon Laboratories, India) as per the methods described by Lumb and Jones (2001), without any sedation. The animals were restrained in standing position and a twitch was applied to minimize the head movements. A 16 gauge needle was inserted into the anterior chamber of the eye through 6-8 O' clock positions of the cornea, approximately 1 mm away from the limbus, as the worm appeared near this site (Fig. 3). Due to the aqueous humor pressure, the eye worm escaped through the needle hub or appeared at the puncture site facilitating its removal. Aqueous leakage was minimal as the needle puncture hole was very small. The puncture site was left as such without suturing in all the treated horses.

All the animals of group B were fasted for 24 hr and water was withheld for 12 hr before surgery. The animals were premedicated with xylazine (1.1mg/kg body weight) given intravenously followed, 5 minutes later, by induction of anesthesia with ketamine (2.2mg/kg bwt, IV). The animals were positioned in

lateral recumbency with affected eye on the upper side. Thereafter, retrobulbar, auriculopalpebral and supraorbital nerve blocks were performed with 2% lignocaine as per the methods described by Lumb and Jones (2001).

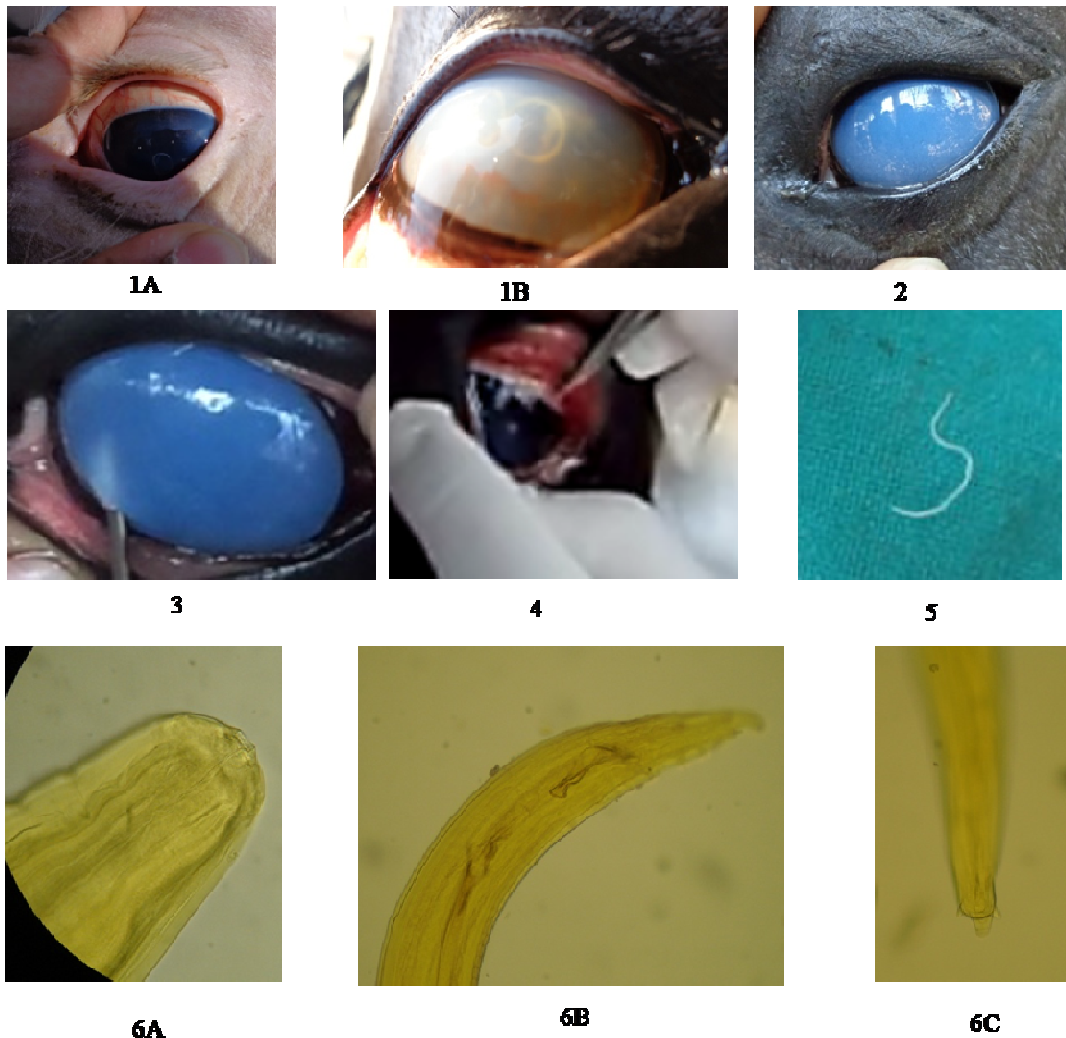
When the eye ball movements were diminished, a nick incision was made between 10-2 O'clock positions on the cornea near limbus using the tip of #11 BP blades (Fig. 4). The parasite was ejected along with the out flow of the aqueous humor in 17 cases (Fig. 2). In two cases, the parasite was removed with forceps. The affected eye was frequently instilled with balanced salt solution to prevent drying of the cornea. The incision site was left as such without suturing. Collected worms (Fig.5) from both groups were washed in Phosphate Buffer Saline (PBS), mounted and identified according to Soulsby (1982) (Fig. 6). Blood samples were obtained randomly from 9 cases for parasitological examination.

Ocular antibiotic drops, Tobramycin (Tobastar®, Lifestar Pharma Private Limited), and Ciprofloxacin (Ciplox®, Cipla Limited, India), 4 drops of each thrice daily were prescribed topically for 2 weeks along with a dose of ivermectin 1g (Hitek®, Virbac Animal Health India Private Limited) orally. Prednisolone acetate eye drops (Pred Forte®, Allergan India Private Limited) were also prescribed to all the cases to manage corneal opacity.

Results

Age of the animals suffering from setariasis ranged between three and eight years. Nineteen animals were males and 7 were females. All the animals had the history of continuous lacrimation and floating worm in the eye for 5-8 days. The clinical examination of the affected eyes revealed varying degrees of corneal opacity and blepharospasms. The swirling movements of the white thread like worm in the aqueous humor were noticed in most of the cases. Heart rate, respiratory rate and rectal temperature were within normal physiological limits in all the cases. Involvement of the left eye was more frequent (19 cases) than the right one (7cases). It was interesting to note that in all the males left eye was involved. Only a single worm was retrieved from all the operated animals. None of the animals was dewormed for last one year.

The animals of group B showed minimal movements during surgical procedure, however, the animals of group A still showed some movements. The eyeball and eyelid movements were comparable in both groups. Success rate of eye worm retrieval was higher (100%) in group B in comparison to that in group A (85.71%). Gradual reduction in lacrimation and corneal opacity was recorded from 5th post-operative day onwards in most of the cases. Due to poor visibility



Figs.1-6: 1A, 1B: Live worm in the eye before surgery; 2: Eye worm induced corneal opacity in a horse; 3: Needle stab aspiration at 7 O' clock position under nerve blocks in group A; 4: Nick incision at 2 O' clock position for eye worm retrieval in group B; 5: Photograph of the parasite removed from the eye; 6: Photographs (A,B,C) show the general morphology of the parasite (A), papilla at anterior end of the parasite (B), and spicule at the posterior end and straight tail (C).

caused by hyphema and non-cooperation of one animal of group A, the worm could not be retrieved. After one month of the first trial, the worm was removed by employing the group B procedure. There was very less aqueous leakage in both groups and there was no complaint of eye ball shrinkage in any group. The procedure used in group A was found more economical (3-4 US Dollars) than the procedure used in group B (16-18, US Dollars).

The horses recovered uneventfully as the corneal opacity subsided gradually and the cornea regained transparency and vision with mild scar in 20-30 days. The retrieved worms were identified as male *Setaria equina* based on the morphology (Fig. 6). Microscopic examinations of the wet film revealed actively motile microfilariae in all the nine blood samples.

Discussion

The adult *Setaria spp.*, commonly found in the peritoneal cavity, is generally regarded as harmless to the host (Mritunjay et al., 2011). However, the heterotrophic parasitism of the worm in the present study caused detrimental changes to the cornea leading to corneal opacity as reported by Gangwar et al. (2008) and Mritunjay et al. (2011) in equine. Basak et al. (2007) reported corneal edema due to dead filarial worm in the anterior chamber with attachment to the endothelium. Possibly, the dead worm liberates toxins into the anterior chamber, which may be lethal to the endothelium and conferring corneal edema. Although both medical and surgical treatments have been advocated for the equine ocular filariasis (Muhammad

and Saquib, 2007), the surgical removal has been adopted in the present study. Inconclusive information is available regarding the techniques used for worm removal either by aspiration or incision and there are pros and cons of both surgical procedures that need to be considered. Both techniques were performed in this study and the incision technique was found to be more suitable.

Needle stabbing technique, as recommended by Singh et al. (1976), was economical and time saving however, application of a 16-gauge needle into the anterior chamber could be quite difficult in aggressive horses. Even though the eye lids and eye ball were properly fixed in group A, some movement was still present which hindered with the surgical interventions. Due to movement, the intervention failed to remove the worm in one case where hyphema was developed during the intervention. Equine cornea is a delicate structure, which could be easily damaged during movement at the time of puncture.

There are reports on the successful removal of intraocular parasites by aspiration from the equine eye (Gangwar et al., 2008) and bovine eye (Shin et al., 2002) using a 16-gauge needle connected to a 5-mL syringe and an 18 gauge needle connected to a 10-mL syringe, respectively. In this study, 16 gauge needles were used just to puncture the cornea near limbus without any aspiration.

The selection of the aspiration device may play a role in the removal of the parasite (Tuntivanich et al., 2011) but we preferred a 16 G needle because of its adequate diameter and to preclude the chance of iris relapse during aspiration. In a study, an 18-gauge needle was used but the worm could not be removed and additional incision on the cornea was required (Tuntivanich et al., 2011). However, no additional incision was required in any case of this study to remove the worm.

Success with anterior chamber paracentesis using almost similar technique has been reported (Morzok and Desouky, 2008), however, the technique was not recommended by Singh et al. (1976) because of a likelihood of shrinkage of the eyeball as a result of aqueous humor effusion. Shrinkage of the eyeball was not noticed in any case of the present study. Regardless of the position of the incision and closure or non-closure of the incision, the eye worm can be removed without aqueous humor effusion (Tuntivanich and Muang, 1979). The ventral position of the cornea was chosen in group A to take advantage of additional gravitational flow of aqueous humor, which might have helped the expulsion of the eye worm. However, alternative incision at a dorsal or lateral-based position has also been proposed (Kalpravidh et al., 1992) because it offers the stability to the incision/ stab postoperatively.

As the size of the puncture could be more with nick incision, we chose 10-2 O' clock positions in group B and corneal wound was left unstitched. Similar incision at a dorsal- position has been proposed (Jamelka, 1976; Kalpravidh et al., 1992), as the chance of eye ball shrinkage due to aqueous effusion is very less. Tuntivanich et al. (2011) also retrieved eye worm successfully under general anesthesia using xylazine-ketamine and isoflurane combination. None of the studies have considered the economical cost of such operations, but in developing and under developed countries, the cost of the intervention may be important factor in deciding the procedure.

A combination of antibiotics and corticosteroids was administered postoperatively to reduce intraocular inflammation and corneal edema. No Corneal opacity was observed after 25 days in the treated animals, possibly due to the minimal surgical manipulations/ intraoperative complications and very good owner compliance. The application of topical steroidal drug together with systemic anti-inflammatory drugs helps reduce inflammation, which influences the degree of corneal edema and uveitis (Tuntivanich et al., 2011)

None of the animals of this study had the history of deworming therefore; all the animals were treated with ivermectin, postoperatively. The incidence of the intraocular filarial nematode may be minimized by treatment with ivermectin at a dose of 200-300 micrograms /kg given orally (Muhammad and Saqib, 2007; Laaksonen et al., 2008).

Conclusion

In conclusion, although removal of ocular parasite through needle paracentesis under regional nerve block analgesia is more economical and less time consuming, the nick incision under general anesthesia is preferable for management of ocular setariasis in horses particularly in aggressive animals.

Acknowledgments

The authors sincerely thank Director, IVRI for the financial help.

References

- Basak, S.K., Hazra, T.K. and Bhattacharya, D. 2007. Persistent corneal edema secondary to presumed dead adult filarial worm in the anteriorchamber. *Indian Journal of Ophthalmology*, 55: 67-69.
- Buchoo, B.A, Pandit, R.A.S., Parrah, J.D. and Darzl, M.M. 2005. Surgical management and prevalence of ocular filariasis in equines. *Indian Veterinary Journal*, 82: 81-82.
- Gangwar, A.K., Sangeetha, D., Singh, H.N. and Singh, A. 2008. Ocular filariasis in equines. *Indian Veterinary Journal*, 85: 547-548.

- Jamelka, E.D. 1976. Removal of *Setaria digitata* from the anterior chamber of the equine eye. *Veterinary Medicine Small Animal Clinician*, 71: 673-675.
- Kalpravidh, M., Bramasa, A. and Kalpravidh, C. 1992. Surgical removals of intraocular parasites from the anterior chambers of the horse eyes. *Thailand Journal of Veterinary Medicine*, 22: 13-20.
- Laaksonen, S., Oksanen, A., Orro, T., Norberg, H., Nieminen, M. and Sukura, A. 2008. Efficacy of different treatment regimes against setariosis (*Setaria tundra*, Nematoda: Filarioidea) and associated peritonitis in reindeer. *Acta Veterinaria Scandinavica*, 50: 49-57.
- Lumb, W.V. and Jones, E.W. 2001. Local and regional anesthetic and analgesic techniques. 2001 In: *Veterinary anesthesia*, 3rd ed. Lea and Febiger, Philadelphia. P: 449.
- Morzok, M.A. and Desouky, A.Y. 2008. Ocular infection of donkeys (*Equus asinus*) with *Setaria equina*. *Tropical Animal Health and Production*, 41: 859-863.
- Mritunjay, K., Monsang, S.W., Pawde, A.M., Singh, S.K., Madhu, D.N., and Zama, M.M.S. 2011. Post surgical healing effect of placentrex in equine (*Equus caballus*) ocular setariasis: A review of 22 cases. *The Indian Journal of Field Veterinarians*, 6: 71-73
- Muhammad, G. and Saqib, M. 2007. Successful treatment of ocular equine microfilariasis (*Setaria* species) with ivermectin. *Veterinary Record*, 160: 25-26.
- Shin, S., Cho, K. and Wee, S. 2002. Ocular infection of cattle with *Setaria digitata*. *Journal of Veterinary Medical Science*, 64: 7-10.
- Singh, H., Chaudhuri, P.C. and Kumar, A. 1976. Paracentesis oculi: a preferred technique for removal of intra-ocular parasites in horses. *Indian Veterinary Journal*, 53: 467-468.
- Solusby, E.J.L. 1982. Helminthis, Arthropods and Protozoa of domesticated animals, 1982. 7th ed. Bailliere, Tindall, London. Pp: 316-319.
- Sreedavi, C., Sudhakar, K., Murthy, P.R. and Prasad, V. 2002. Clinical microfilariasis in a horse: a case report. *Indian Veterinary Journal*, 79: 487-488.
- Townsend, W.M. 2013. Food and fiber-producing animal ophthalmology. In: *Essentials of veterinary ophthalmology*, Gelatt, K.N. (editors). 2nd ed., Wiley-Blackwell, P: 532.
- Tuntivanich, N., Sonthaya, T. and Pranee, T. 2011. Success of Anterior Chamber Paracentesis as a treatment for Ocular Setariasis in Equine Eye: Case Report. *Journal of Equine Veterinary Science*, 31: 8-12.
- Tuntivanich, P. and Muang, M. 1979. *Setaria digitata* in the equine eye. *Thailand Journal of Veterinary Medicine*, 9: 83-88.
- Varma, A.K., Sahai, B.N., Singh, S.P., Lakra, P. and Shrivastava, V.K. 1971. On *Setaria digitata*, its specific characters, incidence and development in *Aedes vittatus* and *Armigeres obturbans* in India with a note on its ectopic occurrence. *Zeitschrift für Parasitenkunde*, 36: 62-72.