

Effects of cigarette smoking on histology of trachea and lungs of albino rat

Shraideh Ziad^{1*}, Al-Awaida Wajdy² and Badran Darwish³

¹Department of Biological Sciences, Faculty of Science, The University of Jordan, Amman, Jordan; ²Department of Biology and Biotechnology, American University of Madaba, Madaba, Jordan; ³Department of Anatomy and Histology, Faculty of Medicine, The University of Jordan, Amman, Jordan

Abstract

This work was an attempt to reveal the effects of a Jordanian cigarette smoke on albino rat tissues at the cellular level. Two groups of male albino rats were exposed to the cigarette smoke for three months on a daily basis, using a special modified smoking machine. Exposure of albino rats for 3 months to cigarette smoke caused drastic histological changes in the tracheal epithelium including epithelial cells proliferation, disruption of its cilia, and presence of inclusion bodies. There was a marked thickening in the alveolar wall of lung alveoli, collapsed alveoli and blood extravasations. These changes indicate that nicotine induced changes similar to those of chronic irritation of tissue may decrease the efficiency of gaseous exchange in alveoli and predispose to neoplastic changes.

Keywords: Cigarette smoking; trachea; lungs; Albino rat

To cite this article: Ziad S, AA Wajdy and B Darwish, 2013. Effects of cigarette smoking on histology of trachea and lungs of albino rat. Res. Opin. Anim. Vet. Sci., 3(10), 356-362.

Introduction

Smoking is the act of inhaling and exhaling the fumes from burning plant materials, especially tobacco. It is consumed in the form of cigarettes, cigars, chew, pipes or water-pipe (Hoffmann and Wynder, 1986).

The smoke generated from burning tobacco is divided into two types: mainstream smoke and sidestream smoke. The mainstream is a type of smoke which is inhaled by the smoker from tobacco product during puffing. The sidestream is the smoke which is emitted by burning cigarette between puffs. The sidestream smoke usually contains higher concentrations of toxic and carcinogenic agents than the mainstream smoke (Stephen, 2010).

Cigarettes contain more than 4,000 identified chemical compounds including 60 known carcinogens (Stephen, 2010). The gaseous components of mainstream smoke (92% of the total smoke) involve 400-500 different gases which include carbon-monoxide, nitrogen oxide, hydrogen cyanide, formaldehyde and ozone. Particulate matter (8% of mainstream smoke) contains tar product such as naphthalene, pyrene and nitrosamine (Ding et al., 2008; Stephen, 2010).

Cigarette smoke contributes to several non-cancer conditions in the respiratory tract, including chronic obstructive pulmonary disease (COPD), asthma, and pulmonary hypertension, and has adverse effects on the respiratory health of children. Cigarette smoking distorts lung immune homeostasis, compromising respiratory host defense.

Shraideh and Najjar (2011) studied the histological effects of two Jordanian Narghile smoke on the respiratory system of albino rat. They discussed the histological changes in trachea and lung alveoli which result from narghile smoke.

This work aims to study the effect of cigarette smoking on selected tissues of the respiratory system of albino rat.

Aims of the work

1. To examine the histopathological changes that may occur during chronic exposure of rats to mainstream cigarette smoke, using a special smoking machine. In this investigation, selected tissues of the respiratory systems (trachea, lung alveoli) have been examined by light microscopy with special emphasis focusing on changes in the epithelium

Corresponding author: Shraideh Ziad, Department of Biological Sciences, Faculty of Science, The University of Jordan, Amman, Jordan

2. To study the recovery of histopathological changes by light microscopy, three months after stopping rat exposure to mainstream cigarette smoke.

Materials and Methods

Experimental design

Sixty male Albino rats (*Rattus norvegicus*), with an average weight of 100-150 g were divided into two groups. The first group (test) was exposed to cigarette smoke while the second group (control) was left untreated. The exposure to smoking was carried out as one dose daily (1 cigarette/rat) for a period of 90 days, followed by a period of three months of non-exposure to smoking as a recovery stage from the effects of cigarette smoking. Following each period, the histological study was performed. Control animals were placed in the chamber and were exposed to fresh air instead of cigarette smoke.

The digital smoking machine

Exposure of animals to cigarette smoke has been done using an electronically controlled smoking machine (Shraideh et al., 2011).

The effects of cigarette smoke on histology of the respiratory systems

Preparation of tissues for light microscopy

Following an overnight recovery from the last smoke exposure, rats were sacrificed by ether anesthesia and tissues of interest (trachea, alveoli of the lung) were gently dissected out, washed well with normal saline (0.9% NaCl), and fixed in 10% saline buffered formalin for at least 24 hrs. To ensure adequate fixation, the formalin fixative was used at volume 10-20 times more than the volume of tissue pieces. Dehydration was achieved by passing tissues through a graded series of alcohol followed by two changes of xylene. After infiltration in paraffin wax, tissues were embedded in pure paraffin wax (Avti et al. 2006).

Sections (5µm thick) were obtained by a microtome (Spencer 50). Finally sections were mounted on glass slides and stained with hematoxylin and eosin. Sections were examined and photographed using Zeiss photomicroscope 1, equipped with Moticam 2300 digital camera/ 3.0 Mega pixels.

Results

The effect of cigarette smoke and its recovery by light microscopy Effect on the trachea

Control sections showed normal ciliated pseudostratified columnar epithelium, mucosal and fibroelastic layers in tracheal tissue (Fig. 1 and 2). The

tracheal mucosa of cigarette smoke-exposed group was adversely affected; showing an epithelial cellular hyperplasia with ciliary amargation, presence of inclusion bodies, and inflammatory cell infiltration (Fig. 3, 4 and 5). After the recovery period, the tissue showed partial recovery (Fig. 6 and 7).

Effect on alveoli of the lung

Photomicrographs of lung alveoli from control animals revealed the normal appearance of their characteristic simple epithelium and terminal bronchiole (Fig. 8, 9 and 10). Lung alveoli of cigarette smoke-exposed rats showed clear thickening in the alveolar wall tissue, collapsed alveoli, inflammatory cell infiltration and blood extravasations (Fig. 11, 12, 13, 14 and 15). After the recovery period, the high degree of proliferating cells was relatively reduced (Fig. 16, 17, 18, 19 and 20).

Discussion

Effect of cigarette smoke on the trachea

In the present study, mucosa disruption that was frequently observed within the tracheal epithelium was due to cell degeneration. Also, ciliary amargation that could be viewed as part of epithelial disruption, might result from the hyperplasia of mucus-secreting submucosal glands, and affect the airway clearance mechanisms. Inclusion bodies (any small amorphous blackish aggregate of smoke toxicants, primarily tar components) were observed.

The observed loss of cilia might be related to the high concentration of nicotine having destructive effects on microtubules and alteration of their polymerization/ depolymerization. Acetaldehyde and acrolein were suspected to play a role in the damage of cilia. Acetaldehyde was able to impair the ciliary function and beat frequency, by inhibiting ciliary dynein ATPase activity, and binding to ciliary proteins critical in the functioning of dynein and tubulin. Acrolein was found to adversely perturb the cilia by reducing its beat frequency, in cultured bovine bronchial epithelial cells (Dye and Adler, 1994). The effect of cigarette smoke on trachea tissue of Wistar rat showed several morphological changes in the epithelium, including desquamation, loss of cilia and an increase of goblet cells. Activation of serous glands in the submucosa, and cell infiltration were also noted. These morphological changes were correlated with the amount of toxic substances in the cigarette smoke (Kurus et al. 2009). The infiltrating inflammatory cells during chronic inflammation, amplifies the tissue damage by releasing more oxygen free radical or through secretion of lytic enzymes (Masubuchi et al. 1998). Gaafar and Al-Mansour (1982) studied the effect of whole cigarette smoke on the tracheal mucosa

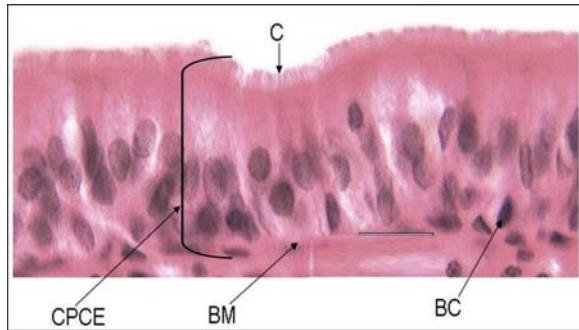


Fig. 1: Section of normal tracheal tissue. CPCE: ciliated pseudostratified columnar epithelium, C: cilia, BM: basement membrane, BC: basal cell. Magnification: 1120x. H&E stain.

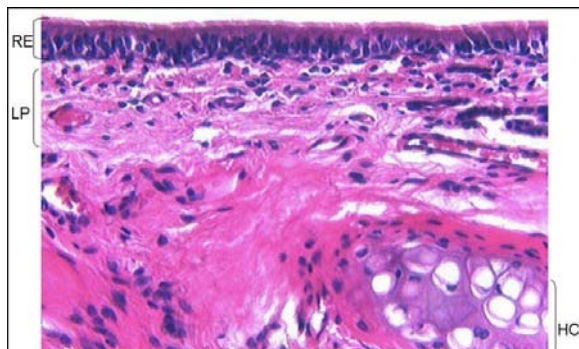


Fig. 2: Section through normal trachea showing its parts. RE: respiratory epithelium, LP: lamina propria, HC: hyaline cartilage. Magnification: 450x. H&E stain.

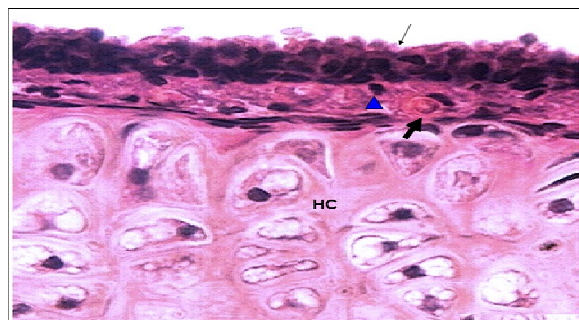


Fig. 3: Trachea of cigarette smoke-exposed rat, showing an epithelial cellular hyperplasia and inflammatory cell infiltration (triangles) with ciliary amalgamation. Thick arrow: blood vessel. Thin arrow: a profound loss of the cilia. Magnification: 1260x. H&E stain.

of the rabbit. They found that the epithelium showed oedema and disturbed stratification, the cilia were sparse and large amorphous bodies and numerous vacuoles were found in the tunica propria. Mikaili et al (2004) studied epithelial and submucosal cell injuries produced following experimental exposure to cigarette

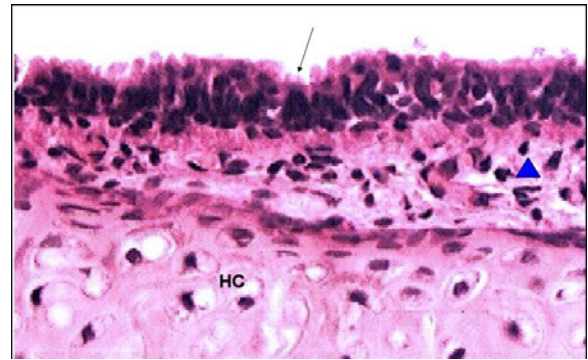


Fig. 4: Section from the tracheal mucosa of cigarette smoke-exposed rat, showing inflammatory cell infiltration (Thick arrows). IB: inclusion body, AC: amalgamated cilia. Epithelial cells are highly proliferated. Magnification: 1185x. H&E stain.

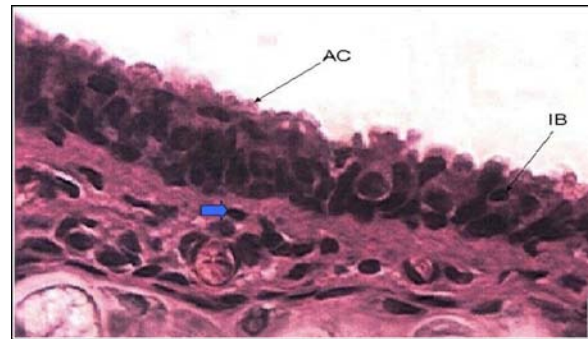


Fig. 5: Trachea of cigarette smoke-exposed rat, showing a high degree of epithelial cellular hyperplasia. Thin arrow: a profound loss of the cilia. Triangle: inflammatory cell infiltration. Magnification: 620x. H&E stain.

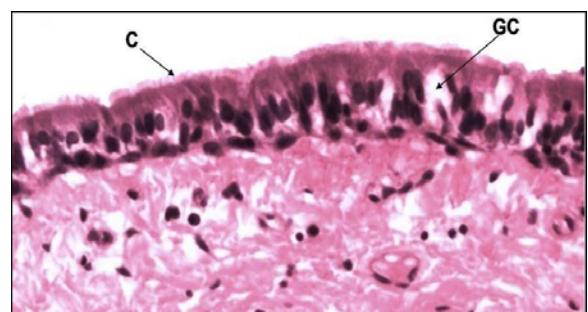


Fig. 6: Section from tracheal mucosa of cigarette smoke-exposed rat after the recovery period, showing returns of cilia nearly toward normal morphology, together with a fewer number of cell proliferation in the epithelium. GC: goblet cell. C: cilia. H&E stain. Magnification: 1250x. H&E stain.

smoke in an experimental setting in rat. Cigarette smoke induced a significant increase in occurrence of metaplasia.

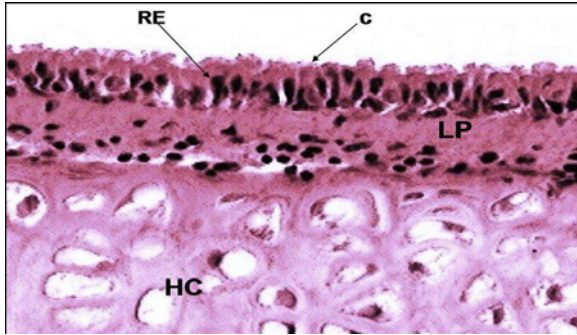


Fig. 7: Trachea of cigarette smoke-exposed rat after the recovery period showing partial recovery of tracheal epithelium. RE: respiratory epithelium, LP: lamina propria, HC: hyaline cartilage. C: cilia. Magnification: 1060x. H&E stain.

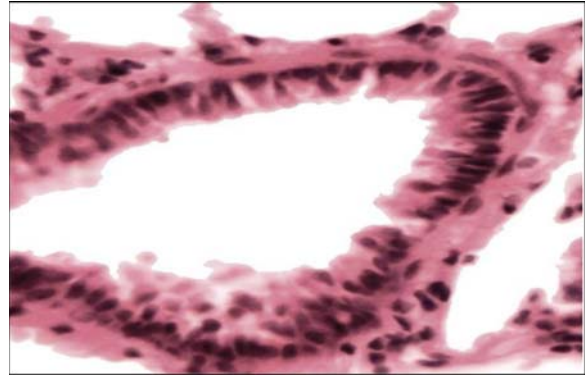


Fig. 10: An enlarged image of a normal terminal bronchiole, showing continuous respiratory epithelium not interrupted by alveoli opening. Magnification: 1350x. H&E stain.

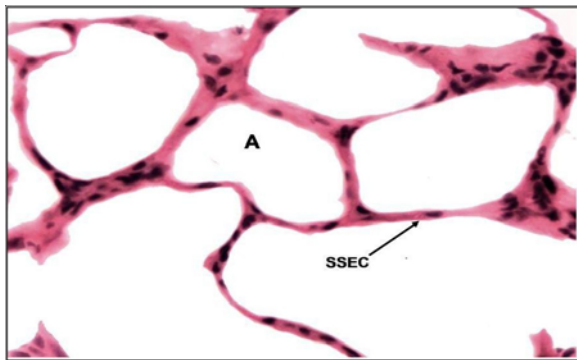


Fig. 8: An enlarged image of a normal lung alveolus. A: alveolus, SSEC: simple squamous epithelial cell. Magnification: 815x. H&E stain.

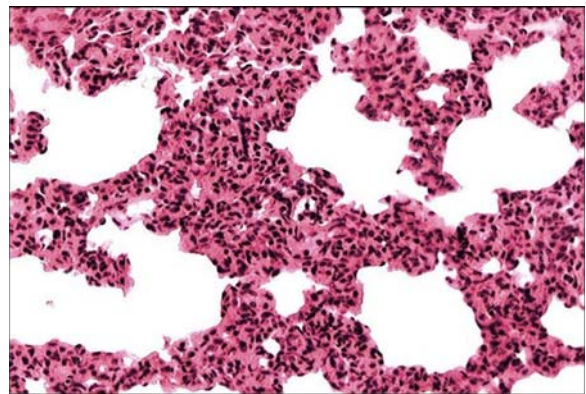


Fig. 11: Lung alveoli of cigarette smoke-exposed rat, showed infiltration of different inflammatory cells, some degree of collapsed alveoli and deposition of collagen fibrils in the alveolar walls. Magnification: 435x. H&E stain

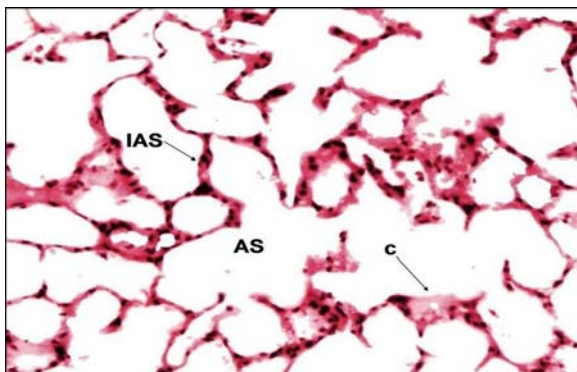


Fig. 9: Control lung alveoli, IAS: interalveolar septum, AS: alveolar sac, C: capillary. Magnification: 270x. H&E stain.

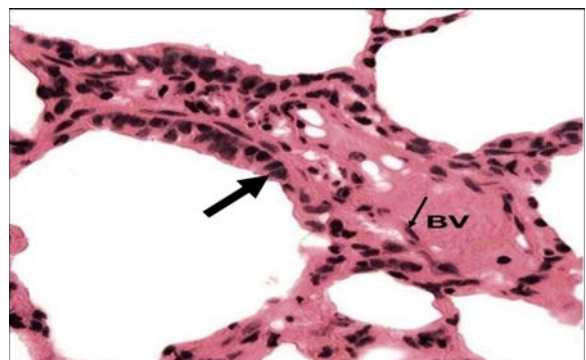


Fig. 12: Lung alveoli of cigarette smoke-exposed rat, showing some degree of thickening in the blood-air barrier. BV: Blood vessel. Thick arrow: type I alveolar epithelial cell. Thin arrow: Endothelial cell. Magnification: 1160x. H&E stain.

Effect of cigarette smoke on the alveoli of the lung

In the present study, lung alveoli of cigarette smoke-exposed rats showed clear thickening in the alveolar wall tissue, collapsed alveoli, inflammatory cell infiltration and blood extravasations. Hyperplasia of alveolar cells was a feature in the affected lung tissue.

Hyperplasia of the alveolar epithelium has been described in a variety of experimental and clinical disorders such as pulmonary edema (Ortega et al., 1970)

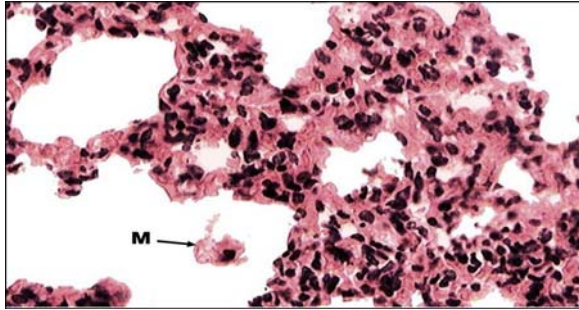


Fig. 13: Lung alveoli of cigarette smoke-exposed rat, showing thickening in the alveolar wall and macrophage is not filled with inclusion bodies (deficient in phagocytosis). M: alveolar macrophage (dust cell). Magnification: 750x. H&E stain.

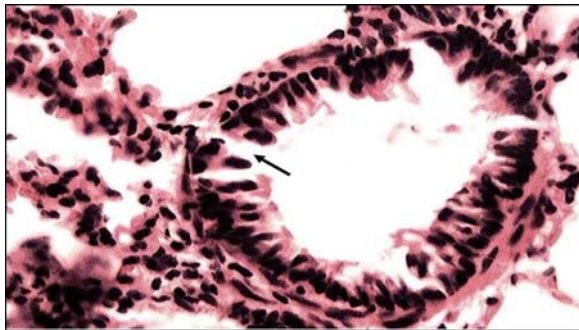


Fig. 14: An enlarged image of a terminal bronchiole of cigarette smoke-exposed rat, showing disturbed respiratory epithelium, and an epithelial cell hyperplasia. Magnification: 900x. H&E stain.

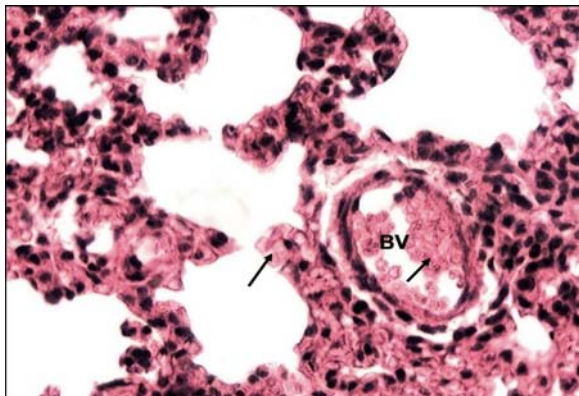


Fig. 15: Lung alveoli of cigarette smoke-exposed rat, showing blood extravasation. Arrow: Erythrocyte. Magnification: 750x. H&E stain.

carcinogens (Kaufman, 1972) and radioactive material (Sanders et al., 1971).

Cigarette smoke caused an accumulation of inflammatory cells in the lung tissue in the present study. These inflammatory cells may contribute in

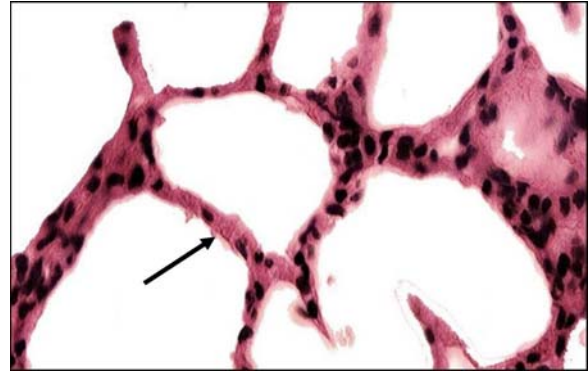


Fig. 16: Lung alveoli of cigarette smoke-exposed rat after the recovery period, showing partial recovery of lung alveoli. Arrow showing thickening in the alveolar wall Magnification: 780x. H&E stain.

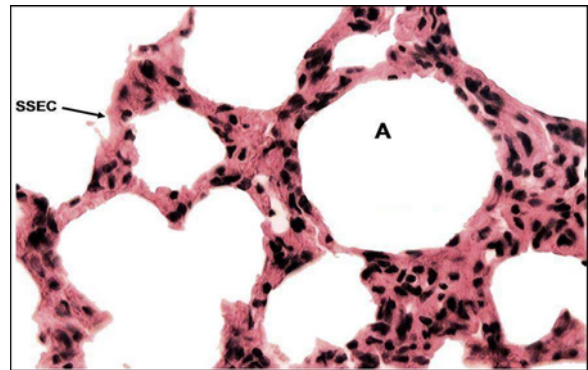


Fig. 17: Lung alveoli of cigarette smoke-exposed rat after partial recovery, showing less thickening in the alveolar wall. A: alveolus, SSEC: simple squamous epithelial cell. Magnification: 745x. H & E stain.

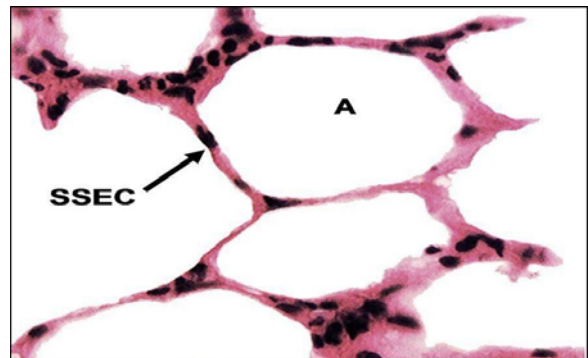


Fig. 18: Lung alveoli of cigarette smoke-exposed rat after the partial recovery. Much less thickening in the alveolar wall and no inflammatory cell infiltration was observed. A: alveolus, SSEC: simple squamous epithelial cell. Magnification: 1380x. H&E stain.

damaging of the alveolar and interstitial pulmonary structures through secretion of lytic enzymes and oxygen free radical (Masubuchi et al., 1998).

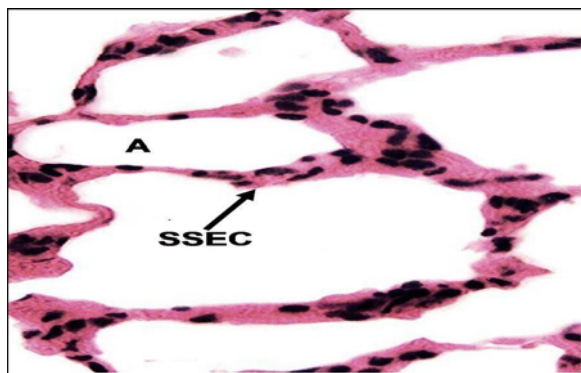


Fig. 19: Lung alveoli of cigarette smoke-exposed rat after the partial recovery, showing less thickening in the alveolar wall. A: alveolus, SSEC: simple squamous epithelial cell. Magnification: 1750. H&E stain.

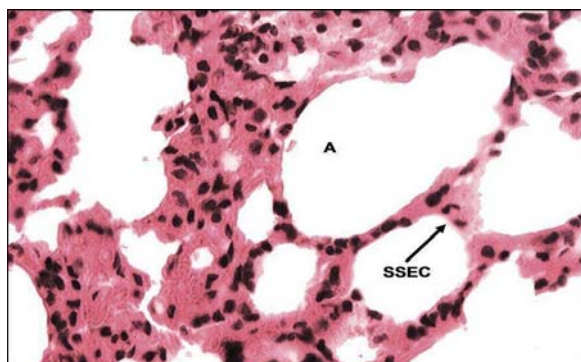


Fig. 20: Lung alveoli of cigarette smoke-exposed rat after partial recovery, showing some regions of thick alveolar walls. A: alveolus, SSEC: simple squamous epithelial cell. Magnification: 890x. H&E stain.

Recovery period

In the present study, tissues of trachea, lung alveoli, aorta showed a partial recovery after cigarette smoke cessation. However, Pekmez et al. (2010) found that the histopathological changes of rat kidney tissue exposed to smoking partially disappeared after treatment with the antioxidant compound caffeic acid phenethyl ester.

Conclusion

Smoking induces histopathological changes in the respiratory passages and aorta that affects the gaseous exchange and may predispose to cancerous changes. Cessation of exposure to cigarette smoking is important to revert all these changes.

Acknowledgment

This work was supported by a grant from the Deanship of Scientific Research/ The University of Jordan (Grant# 1121/2007), given to Dr. Ziad Shraideh,

and was carried out during his sabbatical year (The academic year 2011/ 2012).

References

- Avti, A., Kumar, S., Pathak, C., Vaiphei, K. and Khanduja, K. 2006. Smokeless tobacco impairs the antioxidant defense in liver, lung, and kidney of rats. *Toxicological Sciences*, 89: 547-553.
- Ding, Y., Zhang, L., Jain, R., Jain, N., Wang, R., Ashley, D. and Watson, C. 2008. Levels of tobacco-specific nitrosamines and polycyclic aromatic hydrocarbons in mainstream smoke from different tobacco varieties. *Cancer Epidemiology, Biomarkers and Prevention*, 17: 3366-71.
- Dye, J. and Adler, K. 1994. Effects of cigarette smoke on epithelial cells of the respiratory tract. *Thorax*, 49: 825-834.
- Gaafar, H.A. and Al-Mansour, A.H. 1982. The effect of cigarette smoke on the tracheal mucosa of the rabbit. An electron microscopic study. *Journal of Laryngology and Otology*, 96: 943-950.
- Hoffmann, D. and Wynder, E. 1986. Chemical constituents and bioactivity of tobacco smoke. *International Agency for Research on Cancer*, 74: 145-65.
- Kaufman, S.L. 1972. Alterations in cell proliferation in mouse lung following urethane exposure. *The American Journal of Pathology*, 68: 317-324.
- Kurus, M., Firat, Y., Cetin, A., Kelles, M. and Otlu, A. 2009. The effect of resveratrol in tracheal tissue of rats exposed to cigarette smoke. *Inhalation Toxicology*, 21: 979-984.
- Masubuchi, T., Koyama, S., Sato, E., Takamizawa, A., Kubo, K., and Sekiguchi, M. 1998. Smoke extract stimulates lung epithelial cells to release neutrophil and monocyte chemotactic activity. *The American Journal of Pathology*, 153: 1903-1912.
- Mikaili, P., Sarahroodi, S., Hemmati, A.A., Koochak, M.H. and Akbari, Z. 2004. A histological study on the effects of aqueous extract of *Althea officinalis* on epithelial and submucosal mucociliary system of rat trachea following inhalation of cigarette smoke. *Iranian Journal of Pharmaceutical Research*, 3: 56-57.
- Pekmez, H., Ogeturk, M., Ozyurt, H., Sonmez, M.F., Colakoglu, N. and Kus, I. 2010. Ameliorative effect of caffeic acid phenethyl ester on histopathological and biochemical changes induced by cigarette smoke in rat kidney. *Toxicology and Industrial Health*, 26: 175-82.
- Sanders, C.L., Adey, R.R., and Jackson, T.A. 1971. Fine structure of alveolar areas in the lung following inhalation of 2sgPuOZ particles. *Archives of Environmental Health*, 22: 525-533.
- Shraideh, Z. and Najjar, H. 2011. Histological changes in tissues of trachea and lung alveoli of Albino rats

- exposed to the smoke of two types of Narghile Tobacco Products. *Jordan Journal of Biological Sciences*, 4: 149-156.
- Shraideh Z., Awaida W., Najjar H. and Musleh M. 2011. A modified smoking machine for monitoring the effect of tobacco smoke on albino rats. *Jordan Journal of Biological Sciences*, 4: 109-112.
- Stephen, M. 2010. The toxicological of cigarette smoke and environmental tobacco smoke. *Report Assignment-Biochemical Toxicology*, BC4927.